



Article/Artigo

Comparison between clinical and ultrasonographic findings in cases of periportal fibrosis in an endemic area for schistosomiasis mansoni in Brazil

Comparação entre achados clínicos e ultrassonográficos no diagnóstico da fibrose periportal em uma área endêmica de esquistossomose no Brasil

Aluizio Prata¹, Raiza Ruiz-Guevara¹, Carlos Mauricio de Figueiredo Antunes², Carolina Coimbra Marinho², Leonardo Campos Queiroz², Izabela Voieta² and José Roberto Lambertucci²

ABSTRACT

Introduction: Abdominal palpation and ultrasound findings among patients from an endemic area for schistosomiasis in Brazil who had been followed up for 27 years were compared. **Methods:** In 2004, 411 patients from Brejo do Espírito Santo, in the State of Bahia, were selected for the present investigation after giving their written informed consent. Based on clinical data, they were divided into three groups: 41 patients with evidence of liver fibrosis in 2004 (Group 1); 102 patients with evidence of liver fibrosis in the past (1976-1989) but not in 2004 (Group 2); and 268 patients without evidence of liver fibrosis at any time during the 27-year follow-up (Group 3). All of the patients underwent abdominal ultrasound in which the examiner did not know the result from the clinical examination. The data were stored in a database. **Results:** The prevalence of periportal fibrosis on ultrasound was 82.9%, 56.9% and 13.4% in Groups 1, 2 and 3, respectively. In the presence of hard, nodular liver or prominent left lobe and a hard palpable spleen, ultrasound revealed periportal fibrosis in 70.9%. However, periportal fibrosis was diagnosed using ultrasound in 25.4% of the patients in the absence of clinical evidence of liver involvement. Thus, ultrasound diagnosed periportal fibrosis 3.1 times more frequently than clinical examination did. **Conclusions:** Although clinical examination is important in evaluating morbidity due to Manson's schistosomiasis in endemic areas, ultrasound is more accurate in diagnosing liver involvement and periportal fibrosis.

Key-words: Schistosomiasis. Abdominal ultrasound. Clinical examination. Periportal fibrosis.

RESUMO

Introdução: Neste estudo, se comparou os achados da palpação abdominal e do ultrassom em pacientes de área endêmica de esquistossomose que foram acompanhados por 27 anos no Brasil. **Métodos:** Em 2004, 411 pacientes de Brejo do Espírito Santo, no estado da Bahia, após consentimento informado e por escrito foram selecionados para o presente estudo. Baseando-se no exame clínico eles foram divididos em 3 grupos: 41 (Grupo 1) com evidência de fibrose hepática no ano de 2004; 102 (Grupo 2) com evidência de fibrose hepática no passado (1976-1989) mas não em 2004; e 268 (Grupo 3) sem evidência de fibrose hepática em 27 anos de seguimento. Todos foram submetidos a exame ultrassonográfico do abdome em que o examinador não sabia o resultado do exame clínico. Os dados foram armazenados em banco de dados. **Resultados:** A prevalência de fibrose periportal ao ultrassom foi de 82,9%, 56,9% e 13,4% nos Grupos 1, 2 e 3, respectivamente. Na presença de fígado duro, nodular ou lobo esquerdo proeminente e baço palpável duro, o ultra-som revelou fibrose periportal em 70,9%. Porém, fibrose periportal foi diagnosticada através do ultrassom em 25,4% dos pacientes, na ausência de evidência clínica de envolvimento hepático. Assim, o ultrassom diagnosticou fibrose periportal 3,1 vezes mais frequentemente que o exame clínico. **Conclusões:** O exame clínico tem importância na avaliação da morbidade da esquistossomose mansônica em áreas endêmicas, mas o ultrassom mostra-se mais preciso quando se pretende diagnosticar o envolvimento hepático e a fibrose periportal.

Palavras-chaves: Esquistossomose. Ultrassom abdominal. Exame clínico. Fibrose periportal.

1. Graduate Course on Tropical Medicine and Infectology, University of Triângulo Mineiro, Uberaba, Minas Gerais, Brazil. 2. Graduate Course on Health Sciences: Infectology and Tropical Medicine, School of Medicine, Federal University of Minas Gerais, Belo Horizonte, MG, Brazil.

Address to: Dra Raiza Ruiz-Guevara. Av San Juan Bosco, Ed. Belveder A-62. Altamira, Caracas 1062, Venezuela. Ph: 58-212 2652559, Fax: 58-212 6930454. e-mail: raizaruiz@yahoo.com

Received in 11/09/2009

Accepted in 05/03/2010

INTRODUCTION

Periportal fibrosis, first described by Symmers in 1904¹, can produce portal hypertension and the formation of gastroesophageal varices. Rupture of these varices causes digestive hemorrhage, the most frequent and feared complication of hepatosplenic Manson's schistosomiasis. The hepatosplenic form is the usual clinical counterpart of periportal fibrosis. In clinical-epidemiological studies conducted in endemic areas, morbidity used to be evaluated only on the basis of physical examination of the abdomen. However, there is no consensus about the clinical parameters of the liver and spleen that should be considered in the evaluation. Hepatomegaly and splenomegaly have no uniform definition. The limit for determining that an increase in liver volume has occurred remains a debatable issue.

Some investigators consider hepatomegaly to be present when the organ exceeds the costal margin by 5cm along the sternal line or by 4cm along the midclavicular line². Others accept enlargement to be present if the liver is palpable 2cm below the costal margin³ or simply if the liver is palpable⁴, without mentioning whether this organ is palpable at rest or during inspiration. Yet other investigators attribute more importance to liver characteristics such as hard consistency, presence of nodules on the liver surface or prominence of the left lobe⁵. Regarding the spleen, palpability would be sufficient for some physicians⁶⁻⁸, whereas others believe that the spleen should be palpable at the costal margin or beyond it⁹. Thus, the diagnosis of hepatosplenic schistosomiasis varies according to the different criteria mentioned.

The routine use of abdominal ultrasound examination has been of great help in studying schistosomiasis because it enables identification of periportal fibrosis¹⁰⁻¹⁴. It also provides other important information such as sound evidence of portal hypertension and can measure or better estimate organ sizes¹⁵⁻¹⁸.

The present study was designed to compare clinical and abdominal ultrasound findings in order to determine: a) whether clinical alterations suggestive of liver and/or spleen involvement in schistosomiasis are confirmed by ultrasound; b) the association between periportal fibrosis and other ultrasound findings; and c) the agreement between organ sizes measured by clinical examination and by ultrasound.

METHODS

Study population

A cross-sectional study was conducted in Brejo do Espírito Santo in 2004, a rural community in the municipality of Santa Maria da Vitória, Bahia; this area does not present malaria transmission but is considered hyperendemic for schistosomiasis. A total of 3,766 people have been followed up since 1976 by means of clinical and fecal examinations (Kato-Katz technique)¹⁹, and control measures have been implemented.

Physical examination

The same methodology for clinical evaluation was used on all occasions. The right hepatic lobe was examined on the anterior axillary line and the left lobe on the line through the xiphoid appendix. If it exceeded the costal margin, it was measured in centimeters. When the liver was palpable, it was determined whether its consistency was flaccid (lip consistency), slightly hardened (nose tip consistency) or hard (bone consistency), and whether its surface was smooth or nodular. Prominence of the left lobe was defined when this lobe was clearly larger than the right lobe⁵. The spleen was palpated and measured under the costal margin and its consistency was determined. We defined splenomegaly as present only when the spleen was palpable below the left costal margin. The following clinical forms were described: hepatointestinal (palpable liver), hepatointestinal with advanced hepatic lesions (at least one of the following: hard, nodular or prominent left liver lobe), hepatosplenic (hepatointestinal with advanced liver lesions plus splenomegaly) and postsurgical hepatosplenic (histologically proven periportal fibrosis confirmed during surgery)⁹.

Patients with hepatosplenic or hepatointestinal schistosomiasis with advanced hepatic lesions were assumed to have periportal fibrosis and therefore severe clinical disease⁹. Regarding hepatosplenic patients who underwent surgery, only those with hard and/or nodular liver and/or prominent left lobe were assumed to have liver fibrosis.

Based on clinical examinations performed by one of us (AP) just before the field visit of the present study (2004), the patients who were invited to participate in this study were divided into three groups: 41 patients with clinical evidence of liver disease (Group 1); 102 patients with evidence of liver disease in the past (1976-1989) but not in 2004 (Group 2); and 268 patients without evidence of liver disease at any time during the 27-year follow-up (Group 3).

Abdominal ultrasound

The abdominal ultrasound examination was performed using a GE LOGIQ 100 instrument with a convex 3.5 MHz transducer. We used indicators of periportal fibrosis proposed by the Niamey Working Group (Niamey-Belo Horizonte classification)^{20,21}. In accordance with this protocol, periportal fibrosis was classified in degrees (incipient, possible, probable, definite, advanced and

advanced with portal hypertension). The following other parameters were also evaluated: hepatic contours, left lobe hypertrophy, right lobe atrophy, splenomegaly and thickening of the gallbladder wall. The measurements (walls of the intrahepatic portal branches, caliber of the portal vein, left lobe, right lobe and spleen) were adjusted for the patient's height¹⁶.

Statistical analysis

The data were analyzed using the SPSS program for Windows (Version 10.0; Copyright© SPSS Inc., 1989-1999). After performing descriptive analysis of normality and homogeneity of variance, the data were analyzed using the Student's *t*, Pearson and McNemar chi-square tests. Sensitivity and specificity were estimated. The kappa (*k*) concordance index was using as an estimate of reproducibility. In all cases, the null hypothesis was rejected when α was less than 5% ($p < 0.05$).

Ethical

All clinical, laboratory and ultrasound examinations were performed following a masked protocol. The study protocol was approved by the Research Ethics Committees of the University of the Triângulo Mineiro, Federal University of Minas Gerais and the Brazilian National Research Ethics Committee (CONEP).

RESULTS

A total of 411 patients were studied (199 men and 212 women). The mean ages in years for groups 1, 2 and 3 were: 50.3 ± 12.6 , 50.5 ± 12.9 and 39.8 ± 20.5 , respectively. Group 3 volunteers were significantly younger than the individuals in groups 1 and 2.

Table 1 shows that, from 1976 to 2004, there were marked decreases in the prevalence of *S. mansoni* infection and in the parasitic load, as well as a significant decrease in the proportion of patients with hepatosplenic schistosomiasis.

In Group 1, eight (19.5%) patients had hepatointestinal schistosomiasis with advanced liver lesions and 33 (80.5%) had hepatosplenic disease. Among the latter, 11 (33.3%) had undergone splenectomy. The clinical findings are summarized in **Table 2**.

Abdominal ultrasound

Periportal fibrosis was detected in 128 (31.1%) out of the 411 participants. Most of the patients with severe fibrosis were in Group 1 (**Figure 1**). The mean ages for patients with and without fibrosis were 52 and 34 years respectively ($p < 0.01$). There was no gender difference.

The liver and spleen sizes of the different groups are presented in **Table 3**. Ultrasound showed irregular hepatic contours in 11 patients (3%) and gallbladder wall thickening in 114 (29.2%).

Concordance between clinical and abdominal ultrasound examination

There was no relation between palpable right (192/266) or left (153/228) liver lobes and periportal fibrosis on ultrasound. Periportal fibrosis was present in 50 (36.8%) of the 136 patients with a non-palpable right lobe, and in 74 (27.8%) of the 266 with a palpable right liver lobe. Hence, periportal fibrosis was more frequent when the right liver lobe was non-palpable ($p = 0.001$).

There was a statistically significant association between presence of a palpable left liver lobe and periportal fibrosis ($p = 0.001$), and

TABLE 1 - Prevalence of schistosomiasis, mean parasitic load (*Schistosoma mansoni* eggs per gram of feces) and percentage of clinical forms of schistosomiasis in different examinations, Brejo do Espírito Santo, Bahia, Brazil.

<i>Schistosoma mansoni</i> infection and morbidity		Year of study				
		1976	1980	1985	1989	2004
<i>Schistosoma mansoni</i> infection	prevalence (%)	75.2	60.7	44.5	15.2	1.8
	eggs per gram of feces (mean)	802.5	511.1	255.2	265.3	43.5
	hepatointestinal	86.2	67.5	92.3	87.6	94.3
Clinical forms	HI* with advanced hepatic lesions	4.0	14.8	1.9	2.0	0.6
	hepatosplenic	8.0	10.7	4.3	2.5	1.7
	postsurgical hepatosplenic	0.6	1.0	1.1	0.8	2.1

*HI: hepatointestinal.

TABLE 2 - Clinical examination of the study groups, Brejo do Espírito Santo, State of Bahia, Brazil, 2004.

Clinical examination		Group 1		Group 2		Group 3	
		n ^a	%	n ^a	%	n ^a	%
Right lobe	non-palpable	8	20	39	38,6	89	34,1
	palpable	32	80	62	61,4	172	65,9
Left lobe	non palpable	1	2,4	46	45,1	126	48,8
	palpable	40	95,6	56	54,9	132	51,2
Hepatic consistency*	flaccid	3	7,5	57	78,1	173	95,1
	slightly hardened	23	57,5	16	21,9	9	4,9
	hard	14	35	0	0	0	0
Hepatic surface*	smooth	28	77,8	72	100	183	100
	nodular	8	22,2	0	0	0	0
Prominent left lobe*	no	18	45	52	92,9	131	99,2
	yes	22	55	4	7,1***	1	0,8***
Spleen**	non palpable	5	16,1	64	75,3	183	69,6
	palpable only with deep inspiration	10	32,3	20	23,5	75	28,5
	palpable at the costal margin or beyond	16	51,6	1	1,2	5	1,9
Spleen consistency**	flaccid	2	7,4	19	50	59	74,7
	slightly hardened	12	44,4	8	40	18	22,8
	hard	13	48,1	2	6,9	2	2,5

* Excluding non-palpable patients, ** Excluding splenectomized patients, *** Doubtful.

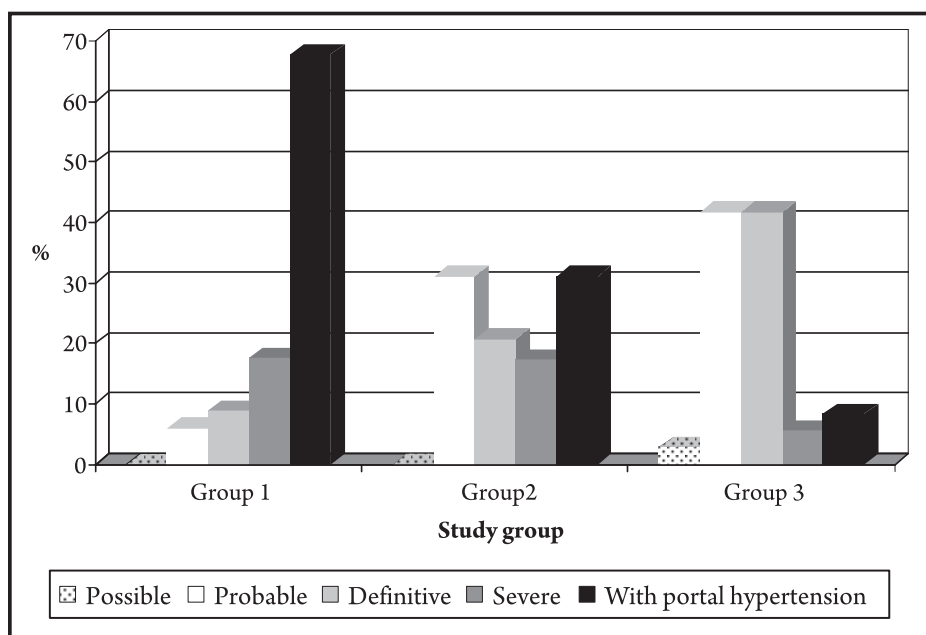
**FIGURE 1 - Degrees of periportal fibrosis in the study groups, Brejo do Espírito Santo, State of Bahia, Brazil, 2004.**

TABLE 3 - Results from clinical examination and abdominal ultrasound and their relationship with periportal fibrosis and portal hypertension, Brejo do Espírito Santo, State of Bahia, Brazil, 2004.

Evaluated parameter	N	Fibrosis		Portal hypertension		
		n ^a	%	n ^a	%	
Clinical examination	right hepatic lobe non-palpable	136	50	36,8*	14	28
	left hepatic lobe beyond the costal margin	131	60	45,8*	26	43,3
	hardened liver	14	11	78,6*	5	45,4
	nodular liver	8	7	87,5*	4	57,1
	prominent left hepatic lobe	27	19	70,4*	12	63,1
	spleen palpable only with deep inspiration	105	22	22,9*	10	9,5
	spleen at the costal margin or beyond	22	16	72,7*	15	93,8*
	hardened spleen	17	16	94,1*	14	87,5*
Abdominal ultrasound	right hepatic lobe atrophy	56	37	66,1*	17	46
	left hepatic lobe enlargement	167	47	28,1	21	44,7
	splenomegaly	38	23	60,5*	20	87*
	irregular liver contours	11	11	100*	5	45,5
	thickening of the gallbladder wall	114	100	87,7*	37	37

*Statistically significant.

this finding was more apparent in Group 1. Eleven (78.6%) out of the 14 patients with a hardened liver, 32 (66.7%) out of the 46 patients with a slightly hardened liver and 46 (19.7%) out of the 233 patients with a flaccid liver had periportal fibrosis on ultrasound. Periportal fibrosis was also found in seven (87.5%) out of the eight patients with nodular liver and in 78 (27.6%) out of the 283 patients with smooth liver surface. Periportal fibrosis was detected in 19 (70.4%) out of the 27 patients with a prominent left lobe and in 107 (28.5%) out of the 375 patients without a prominent left lobe. All these differences were statistically significant ($p=0.001$). These associations were not observed with portal hypertension.

Periportal fibrosis was present in 61 (24.2%) out of the 252 patients with a non-palpable spleen, and in 24 (22.9%) of the 105 patients with a spleen that was only palpable during deep inspiration. Interestingly, 16 (72.7%) out of the 22 patients presenting enlarged spleen had periportal fibrosis ($p<0.004$) and portal hypertension ($p<0.004$). A hardened spleen was also associated with periportal fibrosis (16 out of 17 patients) and portal hypertension (14 out of 17 patients) ($p<0.001$).

In Group 1, 34/41 (82.9%) showed periportal fibrosis on ultrasound, and among them, 23 (67.7%) had portal hypertension. In Group 2, 58/102 (56.9%) had periportal fibrosis, and 18 (31%) had portal hypertension. In Group 3, 36/269 (13.4%) had periportal fibrosis and three (8.3%) had portal hypertension (**Figure 1**). Groups 2 and 3 were pooled together and compared with Group 1, and this showed that periportal fibrosis was significantly higher in Group 1 ($p<0.001$).

Comparison between other ultrasound findings and periportal fibrosis

Thirty-seven (66.1%) out of the 56 patients with right liver lobe atrophy had periportal fibrosis, as opposed to 89 (25.5%) out of the 349 patients with normal right liver lobe ($p < 0.0001$). This was not observed for the left liver lobe.

Twenty-three (60.5%) out of the 38 patients with splenomegaly diagnosed using ultrasound had periportal fibrosis, as opposed to 84 (24.1%) out of the 348 without splenomegaly ($p < 0.001$). Splenomegaly was also associated with portal hypertension (**Table 3**).

Irregular hepatic contours and thickening of the gallbladder wall were associated with periportal fibrosis (**Table 3**). A good agreement was found between gallbladder wall thickening and periportal fibrosis ($kappa = 0.8$).

Comparison of liver and spleen size determined on clinical examination and ultrasound

Twenty-eight (50.9%) out of the 55 patients who had right liver lobe atrophy on ultrasound had a palpable liver. Conversely, 50 (30.5%) out of the 164 patients with an enlarged left lobe on ultrasound had a non-palpable left liver lobe.

Among the 125 patients with a palpable spleen, ultrasound confirmed the presence of splenomegaly in 31 (24.8%). On the other hand, six (15.8%) out of the 38 patients with splenomegaly on ultrasound had a non-palpable spleen.

DISCUSSION

Palpable right liver lobe and palpable spleen are not good indicators of periportal fibrosis in field-based work. Among the cases of a prominent, hard nodular palpable liver, ultrasound revealed periportal fibrosis in 70.9%. It is worth noting that periportal fibrosis occurred in 25.4% of the patients without clinical evidence of liver involvement. In addition, ultrasound diagnosed periportal fibrosis 3.1 times more frequently than clinical examination would suggest. Even in the cases with severe periportal fibrosis on ultrasound, with or without portal hypertension, ultrasound diagnosed 2.1 times more cases than clinical examination did.

Regarding the size of the right liver lobe, there was more fibrosis when this lobe was non-palpable and even more when the lobe was found to be atrophic by ultrasound, as has been previously reported^{2,11}.

With reference to the size of the left hepatic lobe, Houston et al²² observed that hepatomegaly showed high specificity (94%), but low (28%) sensitivity as a fibrosis marker. It is common knowledge that the liver size decreases with increasing degree of fibrosis^{15,22-24}. Doehring-Schwedtsfeger et al²⁵ found no relationship between liver size and periportal fibrosis on ultrasound. In the present study, the association between left liver lobe beyond the costal margin and periportal fibrosis was important only for Group 1, when the left

lobe was also prominent. Thus, we do not think that increased left lobe size alone is a good clinical marker of hepatic fibrosis. When analyzing left lobe hypertrophy on ultrasound, Cerri et al¹¹ and Kardorff et al² detected correlation with portal fibrosis, a finding that was not confirmed in our study.

A distinction should be made between small and large spleen sizes. Only in individuals with large spleens has a relationship with liver fibrosis been found. Thus, in endemic areas, the importance of small palpable spleens is uncertain; it may or may not be related to schistosomiasis (initial stages of the disease). Other causes of splenomegaly should be investigated, as reported by Lambertucci et al²⁶.

In our study, we also detected a relationship between clinical splenomegaly and the WHO fibrosis patterns^{25,27-32}. In addition, patients with severe periportal fibrosis without splenomegaly were also found^{30,33}. Splenomegaly diagnosed using ultrasound was related both to the presence of the WHO patterns and of periportal fibrosis, as already described^{11,20}.

The liver was found by ultrasound to have irregular contours in individuals who had current or past clinical evidence suggestive of periportal fibrosis. However, the absence of irregular contours did not rule out periportal fibrosis. Their presence, as well as gallbladder wall thickening, correlated with periportal fibrosis but not with portal hypertension. This finding has been reported before^{2,14,20,25}. In one study, the finding of gallbladder wall thickening was also suggestive of non-reversal of liver fibrosis³¹.

No agreement was found between ultrasound and clinical examination regarding organ size, as already reported³⁴. One advantage of the Niamey–Belo Horizonte protocol is the adjustment of the measurements to the patients' height²¹. Nonetheless, we occasionally still detected periportal thickening or dilatation of the portal vein in individuals with no qualitative signs of fibrosis on ultrasound (WHO patterns).

Although ultrasound is superior to clinical examination for detection of periportal fibrosis, it does not allow evaluation of important data such as liver and spleen consistency. On the other hand, the subjectivity of clinical examination was unexpectedly demonstrated in the present study: the prevalence of hepatointestinal schistosomiasis with advanced liver disease increased from 4% in 1976 to 14.8% in 1980 and that of hepatosplenic schistosomiasis from 8% to 10.7% (**Table 1**). After a careful investigation, it was noted that a different physician was responsible for the clinical examination in the study area in 1980.

Brejo do Espírito Santo has not been a hyperendemic area for schistosomiasis since the implementation of control measures, which started in 1976. The current clinical and ultrasound findings, many of them slight and some in a regression phase, represent the sequelae from lesions that previously were severe. These were established in the past when *S. mansoni* transmission was high. The implementation of effective measures has changed the disease profile in this area, along with the emergence of hepatosplenic schistosomiasis. However, it is important to emphasize that severe disease persists even after achieving a good control of transmission³¹.

In conclusion, although clinical examination is still important in evaluating morbidity due to Manson's schistosomiasis in endemic areas, ultrasound is more accurate in diagnosing liver involvement and periportal thickening.

CONFLICT OF INTEREST

The authors declare that there is no conflict of interest.

FINANCIAL SUPPORT

FAPEMIG, CNPq and Federal University of Triângulo Mineiro, Brasil

REFERENCES

1. Symmers WSC. Note on a new form of liver cirrhosis due to the presence of the ova of *Bilharzia haematobia*. J Pathol Bacterol 1904;9: 237-239.
2. Kardorff R, Gabone RM, Mugashe C, Obiga D, Ramarokoto CE, Mahlerl C, et al. *Schistosoma mansoni*-related morbidity on Ukerewe Island, Tanzania: clinical, ultrasonographical and biochemical parameters. Trop Med Intern Hlth 1997;2: 230-239.
3. Gryseels B. The morbidity of schistosomiasis mansoni in the Rusizi (Burundi). Trans R Soc Trop Med Hyg 1988;82:582-587.
4. Kong A, Verlé P, Dieng A, Talla I, Rouquet PH. Clinical investigations of a population recently infected with *Schistosoma mansoni* (Richard-Toll, Senegal). Trop Med Intern Hlth 1996;1:191-198.
5. Prata A, Bina JA. Development of the hepatosplenic form of schistosomiasis. Gaz Méd Bahia 1968;68:49-60.
6. Gerspacher-Lara R, Pinto-Silva R, Serufo JC, Rayes AAM, Drummond SC, Lambertucci JR. Splenic palpation for the evaluation of morbidity due to *Schistosoma mansoni*. Mem Inst Oswaldo Cruz 1998;93: 245-248.
7. Kloetzel K. Critério usado para incluir um paciente na forma hepatoesplênica da esquistossomose. In: Program and abstracts of the II Simpósio sobre Esquistossomose. Salvador, Bahia, Brazil; 1970. p. 179.
8. Lambertucci JR, Serufo JC, Gerspacher-Lara R, Rayes AAM, Teixeira R, Nobre V, Antunes CME. *Schistosoma mansoni*: assessment of morbidity before and after control. Acta Tropica 2000;77:101-109.
9. Prata A. Como caracterizar a forma hepatoesplênica da esquistossomose. In: Program and abstracts of the II Simpósio sobre Esquistossomose. Salvador, Bahia, Brazil; 1970. p. 179-184.
10. Abdel-Wahab MF, Esmat G, Farrag A, El-Boraey Y, Strickland GT. Ultrasonographic prediction of esophageal varices in schistosomiasis mansoni. Am J Gastroenterol 1993;88: 560-563.
11. Cerri GG, Alves VAF, Magalhães A. Hepatosplenic schistosomiasis mansoni: ultrasound manifestations. Radiology 1984;153: 777-780.
12. Gerspacher-Lara R, Pinto-Silva R, Rayes AAM, Drummond SC, Lambertucci JR. Ultrasonography of periportal fibrosis in schistosomiasis mansoni in Brazil. Trans R Soc Trop Med Hyg 1997;91: 307-309.
13. Homeida MA, Abdel-Gadir AF, Cheever AW, Bennett JL, Arbab BMO, Ibrahim SZ, et al. Diagnosis of pathologically confirmed Symmers' periportal fibrosis by ultrasonography: a prospective blinded study. Am J Trop Med Hyg 1988;38:86-91.
14. Pinto-Silva RA, Abrantes WL, Antunes CME, Lambertucci JR. Sonographic features of portal hypertension in schistosomiasis mansoni. Rev Inst Med Trop S Paulo 1994;36: 353-361.
15. Abdel-Wahab MF, Esmat G, Farrag A, El-Boraey YA, Strickland GT. Grading of hepatic schistosomiasis by the use of ultrasonography. Am J Trop Med Hyg 1992;46: 403-408.
16. Yazdanpanah Y, Thomas AK, Kardorff R, Talla I, Sow S, Niang M, et al. Organometric investigation of the spleen and liver by ultrasound in *Schistosoma mansoni* endemic and non endemic villages in Senegal. Am J Trop Med Hyg 1997;57: 245-249.
17. Lambertucci JR, dos Santos Silva LC, Andrade LM, de Queiroz LC, Carvalho VT, Voieta I, et al. Imaging techniques in the evaluation of morbidity in schistosomiasis mansoni. Acta Trop 2008;108:209-217.
18. Lambertucci JR, Rocha RS, Carvalho OS, Katz N. A esquistossomose em Minas Gerais. Rev Soc Bras Med Trop 1987;20:47-52.

19. Katz N, Chaves A, Pellegrino J. A simple device for quantitative stool thick-smear technique in schistosomiasis mansoni. *Rev Inst Med Trop S Paulo* 1972;14:397-400.
20. Richter J, Coutinho Domingues AL, Barata CH, Prata A, Lambertucci JR. Report of the Second Satellite Symposium on ultrasound in schistosomiasis. *Mem Inst Oswaldo Cruz* 2001;96 (suppl 1):151-156.
21. Richter J, Hatz C, Campagne G, Bergquist NR, Jenkins JM editors. *Ultrasound in schistosomiasis. A practical guide to standardized use of ultrasonography for the assessment of schistosomiasis-related morbidity.* 2000, Geneva, Switzerland; 2000. World Health Organization, TDR/STR/SCH/00.1.
22. Houston S, Munjoma M, Kanyimo K, Davidson RN, Flowerdew G. Use of ultrasound in a study of schistosomal periportal fibrosis in rural Zimbabwe. *Acta Trop* 1993;53:51-58.
23. Abdel-Wahab MF, Esmat G, Milad M, Abdel-Razek S, Strickland GT. Characteristic sonographic pattern of schistosomal hepatic fibrosis. *Am J Trop Med Hyg* 1989;40:72-76.
24. Richter J, Silva-Monteiro E, Moreira-Braz R, Abdalla M, Abdel-Rahim IM, Fano U, et al. Sonographic organometry in Brazilian and Sudanese patients with hepatosplenic schistosomiasis mansoni and its relation to the risk of bleeding from esophageal varices. *Acta Trop* 1992;51:281-290.
25. Doehring-Schwedtfeger E, Abdel-Rahim IM, Ali QM, Elsheit M, Schlake J, Kardorff R, et al. Ultrasonographical investigation of periportal fibrosis in children with *Schistosoma mansoni* infection: evaluation of morbidity. *Am J Trop Med Hyg* 1990;42:581-586.
26. Lambertucci JR. *Schistosoma mansoni*: pathological and clinical aspects. In: Jordan P, Webbe G, editors. *Human Schistosomiasis*, Cab International, Wallingford, UK; 1993. p. 195-225.
27. Gerspacher-Lara R, Pinto-Silva R, Rayes AAM, Drumond SC, Lambertucci JR. Ultrasonography of periportal fibrosis in schistosomiasis mansoni in Brazil. *Trans R Soc Trop Med Hyg* 1997;91:307-309.
28. Hoffmann N, Esterre P, Ravaolimalala VA, Ehrich JHH, Doehring E. Morbidity of schistosomiasis mansoni in the highlands of Madagascar and comparison of current sonographical classification systems. *Trans R Soc Trop Med Hyg* 2001;95: 623-629.
29. Homeida MA, Ahmed S, Defalla AA, Suliman S, El Tom J, Nash T, et al. Morbidity associated with *Schistosoma mansoni* infections as determined by ultrasound: a study in Gezira, Sudan. *Am J Trop Med Hyg* 1988;39:196-201.
30. Lambertucci JR, Cota GF, Pinto-Silva RA, Serufo JC, Gerspacher-Lara R, Drummond SC, et al. Hepatosplenic schistosomiasis: a combined clinical and sonographic definition. *Mem Inst Oswaldo Cruz* 2001;96 (suppl 1):147-150.
31. Cota GF, Pinto-Silva RA, Antunes CM, Lambertucci JR. Ultrasound and clinical investigation of hepatosplenic schistosomiasis: evaluation of splenomegaly and liver fibrosis four years after mass chemotherapy with oxamniquine. *Am J Trop Med Hyg* 2006;74:103-107.
32. Lambertucci JR, Silva LC, Andrade LM, de Queiroz LC, Pinto-Silva RA. Magnetic resonance imaging and ultrasound in hepatosplenic schistosomiasis mansoni. *Rev Soc Bras Med Trop* 2004;37:333-337.
33. Prata A, Andrade ZA. Fibrose hepática de Symmers sem esplenomegalia. *O Hospital* 1963;63:609-623.
34. Lambertucci JR, Gerspacher-Lara R, Pinto-Silva RA, Barbosa MM, Teixeira R, Barbosa HF, et al. The Queixadinha Project: morbidity and control of schistosomiasis in an endemic area in the Northeast of Minas Gerais, Brazil. *Rev Soc Bras Med Trop* 1996;29:127-135.