

Acromial Morphometric Analysis Using Imaging Software

Análisis Morfométrico del Acromion Usando Software de Imágenes

Lucas Fernandes Crahim^{*}; Akinori Cardozo Nagato^{*}; Carolina de Lourdes Julião Vieira Rocha^{*}; Marco Aurélio dos Santos Silva^{***}; Ana Carla Balthar Bandeira^{***}; Tereza Aparecida Ferreira^{*} & Frank Silva Bezerra^{***}

CRAHIM, L. F.; NAGATO, A. C.; ROCHA, C. L. J. V.; SILVA, M. A. S.; BANDEIRA, A. C. B.; FERREIRA, T. A. & BEZERRA, F. S. Acromial morphometric analysis using imaging software. *Int. J. Morphol.*, 31(1):345-350, 2013.

SUMMARY: The aim of this study was to accurately measure acromial morphology in order to describe the anatomical patterns of its subtypes and to conduct a survey of the literature regarding the relationships between morphological subtypes and their related diseases. We photographed scapulae from the Institute of Anatomy, University Severino Sombra, and analyzed the images using Image-J Software®. The average acromial angle was $139.23^\circ \pm 2.781$, with no significant difference between the right and left sides. There was a positive correlation between the acromial angle and the angle of the spine of the scapula. The correlation mentioned above plays an important role in disorders of the shoulder—particularly impingement syndrome—which reinforces the importance of acromial morphology studies.

KEY WORDS: Acromial morphology; Acromioclavicular; Impingement syndrome; Morphometry.

INTRODUCTION

The glenohumeral joint is used in various day-to-day situations when the shoulder angle exceeds 90° , such as during physical exercise. The overuse of this joint is often associated with injuries such as rotator cuff injuries, bursitis, and tendinitis. Studies have found that the main cause of chronic pain in this joint for baseball, volleyball, handball, and football players as well as for swimmers is the repeated use of the shoulder rotators. For example, swimming is related to tendinitis of the supraspinatus or biceps tendon, which is directly associated with subacromial impingement syndrome.

The shoulder joint complex is considered one of the most unstable joints in the human body because of the shape of its articular surfaces, namely, the humeral head and glenoid cavity (i.e., shoulder blade). This highlights the importance of the involvement of all assets and liabilities of the joint, including the muscles, ligaments, joint capsule, glenoid labrum, and bone structures that stabilize the joint.

This complex is the most mobile one in the body and has 3 degrees of freedom, which allows the arm to be guided in 3 planes of space: (1) the transverse axis, which is included in the frontal plane and allows movements in the sagittal

plane (i.e., flexion/extension); (2) the anterior–posterior axis, which is included in the sagittal plane and allows movement in the frontal plane (i.e., abduction/adduction); and (3) the vertical axis, which is determined by the intersection of the sagittal and frontal planes, and allows movement in the horizontal plane (i.e., internal/external rotation, abduction/adduction, and horizontal movement). Among the movements of the glenohumeral joint related to subacromial impingement syndrome, the most frequent are flexion ($>90^\circ$), abduction ($>90^\circ$), and circumduction. Subacromial impingement syndrome develops in sports participants who perform these moves in activities such as swimming, volleyball, baseball, football, tennis, and handball among others (Kammer *et al.*, 1999). The complex of the shoulder is subject to a variety of injuries that can even be caused by trauma—usually in the form of contact with an external object such as the ground or other individual as well as repetitive joint actions, which create sites of inflammation in and around joint or muscle insertions. Studies show that the impact on the bottom surface of the acromion has its peak strength from $85\text{--}136^\circ$ of elevation; a similar study shows that the bottom surface of the acromion and rotator cuff tendons are in close proximity between 60° and 120° of elevation on the anterior–inferior acromion (Hyvönen, 2003).

^{*} Laboratory of Biomorphometry and Experimental Pathology - Physiotherapy, Severino Sombra University, Vassouras, Rio de Janeiro, Brazil.

^{**} Laboratory of Tissue Repair, Department of Histology and Embryology, Institute of Biology Roberto Alcântara Gomes, Rio de Janeiro State University, Rio de Janeiro, Brazil.

^{***} Human Anatomy Laboratory, Department of Biological Sciences, Federal University of Ouro Preto, Minas Gerais, Brazil.

Neer (1972) was the first to characterize impingement as a distinct clinical entity, giving rise to the term impingement syndrome; in impingement syndrome, it is assumed that rotator cuff injury is not only related to the side of the acromion but also to the anterior third of the acromion, the coracoacromial ligament, acromion, and clavicle. Neer (1972) also suggests that the part of the cuff that undergoes this compression (i.e., the impact zone) is centered at the insertion of the supraspinatus tendon on the greater tubercle of the humerus. Neer (1972) describes impingement syndrome as a clinical syndrome characterized by a continuous spectrum beginning with an inflammatory process, progressing to fibrosis, and ending with rotator cuff tearing. The structures compromised during mechanical impact specifically include the tendon supraspinatus, long head tendon of the biceps, subacromial bursa, and less frequently, the infraspinatus tendon (Depalma & Johnson, 2003). Bigliani *et al.* (1986) first described the relationship of these tendons with acromial impingement syndrome including 3 acromial morphologic types: straight, curved, and hooked; the hooked type is related to impingement. Neer (1983) later divided impingement syndrome into 3 stages: stage I, edema and hemorrhage of the bursa and rotator cuff; stage II, lesions exhibit permanent changes such as fibrosis and tendinitis of the rotator; and stage III, lesions related to chronic changes such as partial rupture and/or complete rotator cuff tear, prevalent in individuals over 40 years of age.

More recently, shoulder impingement syndrome was further divided into 2 categories: internal and external impact. External impact is caused by structural changes outside the joint, which can be classified as primary, secondary, and subcoracoid impact. Primary impact is considered a consequence of degenerative changes of the acromioclavicular joint and acromion morphology. Secondary impact is related to the elevation of the humeral head and/or glenohumeral instability. Subcoracoid impact is related to the impact of the subscapularis tendon and bursa subcoracoid with the lesser tubercle of the humerus. Internal impingement is secondary to dysfunction of the rotator cuff or joint capsule and can be divided into 4 types: posterior–superior (impact classic), anterior–superior, anterior, and imprisonment of the long head tendon of the biceps (Hallström, 2009).

Through these considerations, it is arguable that the morphometric evaluation of the acromial angle using imaging allows us to accurately establish the average acromial angle, thus allowing a project to categorize the acromial subtypes as well as create a better understanding of the actual correlation between these variables and related diseases. Moreover, the study of acromial morphology contributes to the body of information on anthropometric acromial measures.

MATERIAL AND METHOD

This prospective descriptive study involving photographs of human cadaver scapulae was performed at the Institute of Anatomy, Severino Sombra University-RJ (IAUSS) in partnership with the Laboratory of Experimental Pathology and Biomorphometry University Severino Sombra (USS-LBPE) between June and August 2010. This study was approved by the Ethics in Research Committee of Severino Sombra on April 16, 2010 (0007/2010-01).

We used 14 scapulae (8 right and 6 left) from human cadavers at the Institute of Anatomy, University Severino Sombra that were previously fixed and removed from the cadavers for morphometric analysis. To capture images, the scapulae were fixed to a metal rod by the medial margin of the scapula so that the shaft perpendicularly cut the center of the glenoid cavity to stay in the horizontal plane. The shaft was then fixed in a mini vise (Worker®) previously fixed on a wooden bench (30 cm x 40 cm x 2 cm). A compact digital camera (Kodak M340) with a resolution of 10.0 megapixels (3× optical zoom; 36 mm to 108 mm) in auto mode with the macro function enabled (distance <70 cm) was positioned on a tripod 11 cm from the bench in a side view of the glenoid cavity; the camera lens was focused and aligned perpendicularly to the axis cutting through the center of the glenoid cavity (Fig. 1).



Fig. 1. Mounted system for capturing images related to the angles of the slope of the acromion and scapular spine.

The measurements of length and width of the acromion scapulae were fixed through the medial margin so that the upper surface of the acromion was centered on the axis of the camera. The distance between the center of the glenoid cavity and wooden bench, and acromion (see Figure 1) was 12.5 cm; this was the same as the camera height. The distance between the camera and the center of the glenoid cavity or the acromion was 14.5 cm (Fig. 2).

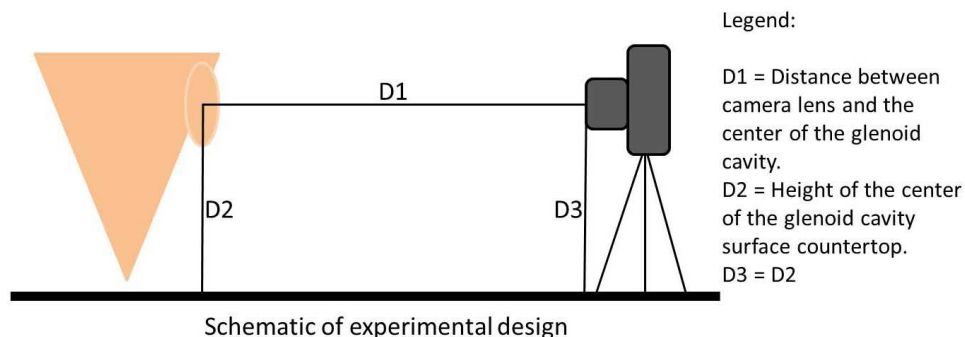


Fig. 2. Schematic of the experimental design for analyzing the angles of the slope of the acromion and scapular spine.

Morphometric Analysis. The images were transferred to a computer at the Laboratory of Experimental Pathology Biomorphometry USS and analyzed using Image-J® software (version 1.32 for Windows). From a known external reference point, digital calipers accurate to within 0.2 mm (Digital Caliper Mitutoyo 500-144B; Automation and Metrology Inc.; Painesville, OH) were used to establish a relationship along (pixels/mm), and the length and width were then measured. During the study, we observed a possible correlation between the acromial and tilt angles of the spine of the scapula that was subsequently analyzed. Morphometric measurements were performed digitally using linear or angular demarcations in Image-J.

Statistical Analysis. Statistical analysis was performed using GraphPad Prism® 5. Differences were considered significant at $p < 0.05$. The normality of sample data was verified using D'Agostino–Pearson test. Differences in parametric data were verified by unpaired t-tests with Welch's correction. Data are expressed as mean \pm standard error of the mean.

RESULTS

Acromial anthropometric data are shown in Table I. The amplitude of the acromial angle ranged from $122.35\text{--}158.70^\circ$ with an arithmetic mean of $139.23^\circ \pm 2.781$. The average width of the measurements was 3.68 ± 1.39 cm. The average acromial length was 3.70 ± 0.21 cm. The average angle of inclination of the scapular spine was $42.01^\circ \pm 2.664$.

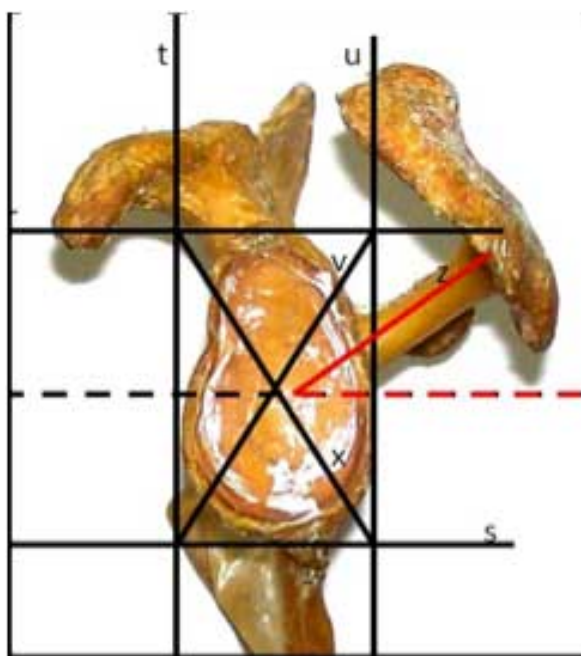


Fig. 3. Measurement of the angle of the spine of the scapula with the central point of the glenoid cavity as a reference. Lines r, s, t, u, v, and x were drawn. Then, a dashed straight line (y) and a straight line (z) passing over the spine of the scapula were drawn, forming the angle between them.

Table I. Acromial anthropometric measurements of anatomical specimens.

| | Average | Standard Error | Test for normality |
|----------------------------------|---------|----------------|--------------------|
| Acromial angle | 139.2° | 2.781 | + |
| Tilt angle of the scapular spine | 42.01° | 2.664 | + |
| Acromial width | 3.68 | 1.39 | + |
| Acromial length | 3.70 | 2.66 | + |

The left and right scapulae had average angles of $143.69^\circ \pm 7.51$ and $135.89^\circ \pm 11.44$, respectively. Scapulae was not statistically significant difference. ($p = 0.21$) (Fig. 4).

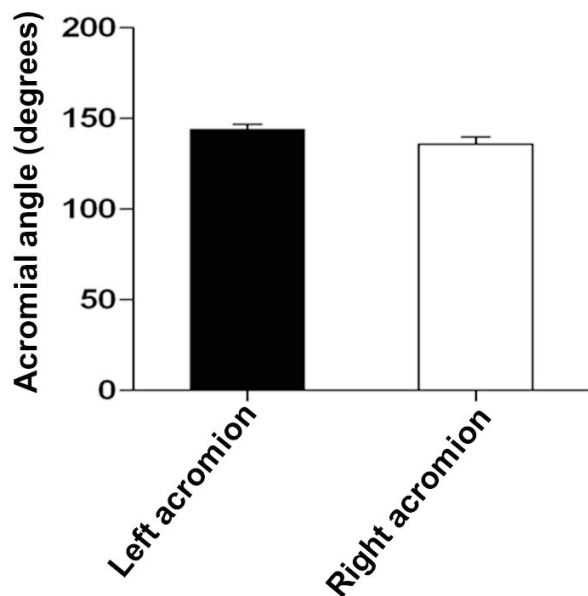


Fig. 4. Comparison between the left and right angles of the acromion of the scapula. The average acromial angle was not significantly different ($p < 0.05$).

There was a directly proportional positive correlation between the values found for the tilt angle of the spine of the scapula and the acromial angle ($r\Sigma = 0.96$, $p = 0.0001$) (Fig. 5).

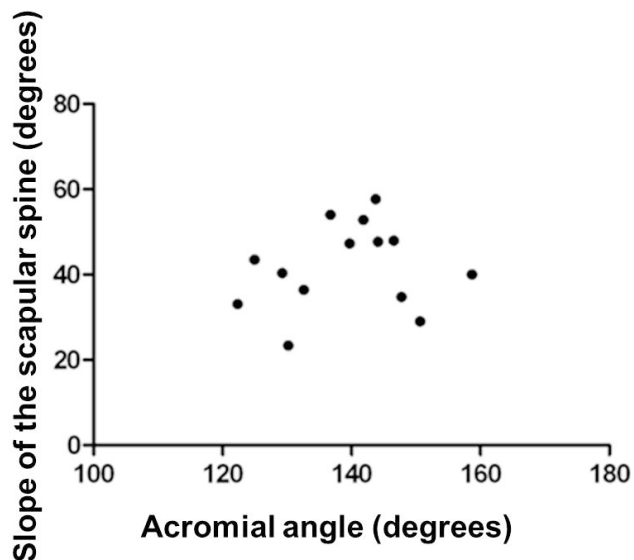


Fig. 5. The angle between the acromial and scapular inclinations exhibit a positive correlation ($r\Sigma = 0.96$, $p = 0.0001$). The regression equation is $y = 0.1747x + 17.683$.

DISCUSSION

The macroscopic observations revealed a close relationship between the acromion, humerus, and its surrounding structures. Although not a focus of this study, in pieces that were still attached, were observed the subacromial space, mostly with very minute spaces. This suggests a relationship between impingement syndrome and the acromion in which a more curved lower space leads to an increased risk of developing the disease.

The present study revealed a positive correlation between the angles of inclination of the acromion and the spine of the scapula. Furthermore, there was no significant difference between the acromial angles of the left and right scapulae, which is corroborated by the literature.

The diversity of the methods used to measure the acromial angle has hampered studies on acromial morphology and related pathologies. Nasca *et al.*, (1984) measured the angle of the bottom of the anterior acromion in radiographs by drawing a straight line through the acromion and another line parallel to its bottom surface; angles considered normal ranged from 15–30°, while 2 cases had angles of 50°.

Meanwhile, Bigliani *et al.*, used a different radiographic technique. Although they started from the same reference point used by Nasca *et al.*, they used a straight line between the extreme points of the acromion instead of a straight line that crossed the acromion. The angles found were 13.1°, 26.9°, and 28.7°, characterizing the flat (type I), curved (type II), and hooked (type III) morphological types (Bigliani *et al.*).

In the present study, we found an average angle of 139.23°; larger angles were further characterized as flat, and the smaller ones as more curved according to the classification by Bigliani *et al.*; Aoki *et al.*, (1986) describe a different technique for the measurement of the acromial angle in which the reference point used is the lower surface of the coracoid process.

Toivonen *et al.*, (1995) introduced the term “acromial angle” in 1995 and described in detail how this angle can be measured from lateral radiographic views of the acromion. Their findings are similar to those of Bigliani *et al.*; the range of variation of the angles of the acromial types were 0–12°, 13–27°, and >27° for types I, II, and III, respectively.

Zuckerman *et al.*, (1992) report the influence of the coracoacromial arch in the rotator cuff, multiple measurements, the angles formed by the anterior and posterior points of the

acromion, and a shaft that runs through the center of the glenoid cavity. Chambler & Emery (1997) also report this; in their systematic review, they summarize the different methods of measurements published from 1984-1995.

Because of the diversity in the methods for measuring the acromial angle found in the literature, we suggest a more precise and reliable method for characterizing the acromion and for analyzing the measured values found with respect to diseases related to the acromion. They were first identified in the most extreme points of the acromion, then a straight line between these 2 points, then to the highest side of the acromion (i.e., the apex of the angle), and lastly, the angle was measured between the 3 points using a software. We believe that this method of measurement is more reliable because it is performed on a pixel-by-pixel basis.

To the best of our knowledge, this is the first study to report the correlation between the angles of the spine and acromion of the scapula. Accordingly, the relationship between the presence of impingement syndrome and the angle of the scapular spine should be studied in the future. Knowledge of the etiologies of impingement syndrome is fundamentally important for better treatment; this highlights the importance of studies outlining the morphological characteristics of the shoulder, especially the acromion. These causes of impingement syndrome (e.g. muscle weakness, degenerative tendinopathy, glenoumeral instability) are widely studied (Bigliani & Levine, 1997); they are classified as intrinsic (intratendinous) and extrinsic (extratendinous). Muscle weakness is also an important factor. Nirschl (1989) reports that impingement syndrome is strongly related to muscle weakness, particularly the supraspinatus muscle; however, this factor is more prevalent in swimmers and throwers. Overuse is also an important intrinsic factor caused by repetitive microtrauma; this also has an important relationship with sports practice (Jobe, 1995).

Among the extrinsic factors, in 1875, Hamilton identified the morphology of the acromion as the main source of shoulder symptoms and noted that the acromial epiphysis

could limit movement due to its slight downward shift (Bigliani & Levine). Furthermore, in 1909, Goldthwait described differences in the slope of the acromion; only in 1972 did Neer focus on the cause-and-effect relationship between the morphology of the acromion and subacromial impingement (Bigliani & Levine).

McLaughlin & Asherman (1951) report the impact on the coracoacromial ligament as another important extrinsic etiological factor of impingement syndrome; this ligament plays a major role in dysfunctions of the shoulder. The macroscopic observations in this study indicate that this relationship as well as the acromial morphology are important given the fact that the impact zone described by Neer, in 1983, maintains a close relationship with the tendon of the supraspinatus muscle, which is the most affected by injuries.

The present gross morphological observations also indicate an important similarity between the angles of the acromial and coracoid processes. Accordingly, other studies investigating the possible positive correlation between these variables may contribute significantly to knowledge related to impingement syndrome.

Because the present study implemented a new method for measuring the acromial angle based on elementary principles of classical geometry and this method has not yet been reported in the literature, comparisons are difficult.

Methods and techniques with the support of various technological resources in basic sciences such as morphology are widely used. These methods are extremely important for a better understanding of diseases and the establishment of more appropriate therapies as a result. However, the wide variety of methods used for measuring the acromial angle is a complicating factor for the diagnosis of pathologies affecting the shoulder, such as impingement syndrome. It is necessary to develop an analytical method that more reliably measures the acromial angle. We stress the importance of further studies using the methods suggested in this study to characterize morphological types of the acromion.

CRAHIM, L. F.; NAGATO, A. C.; ROCHA, C. L. J. V.; SILVA, M. A. S.; BANDEIRA, A. C. B.; FERREIRA, T. A. & BEZERRA, F. S. Análisis morfométrico del acromion con software de imágenes. *Int. J. Morphol.*, 31(1):345-350, 2013.

RESUMEN: El objetivo de este estudio fue medir con precisión la morfología acromial para describir los patrones anatómicos de sus subtipos y llevar a cabo un estudio de la literatura sobre las relaciones entre los subtipos morfológicos y las enfermedades relacionadas. Tomamos fotografías de la escápula del Instituto de Anatomía de la Universidad Sombra Severino, y se analizaron las imágenes con el Software Image-J®. El ángulo acromial medio fue de $139,23 \pm 2,781^\circ$, no habiendo diferencias significativas entre los lados derecho e izquierdo. De observó una correlación positiva entre el ángulo acromial y el ángulo de la columna vertebral de la escápula. La correlación mencionada anteriormente, juega un papel importante en los trastornos de la inflamación del hombro, especialmente el síndrome, lo cual refuerza la importancia de los estudios de la morfología acromial.

PALABRAS CLAVE: Morfología acromial; Acromioclavicular; Síndrome de pinzamiento; Morfometría.

REFERENCES

- Aoki, M.; Ishii, S. & Usui, M. The slope of the acromion and rotator cuff impingement. *Orthop. Trans.*, 10:228, 1986.
- Bigliani, L. U. & Levine, W. N. Subacromial impingement syndrome. *J. Bone. Joint. Surg. Am.*, 79(12):1854-68, 1997.
- Bigliani, L. U.; Morrison, D. S. & April, E. W. The morphology of the acromion and its relationship to rotator cuff tears. *Orthop. Trans.*, 10:228, 1986.
- Chambler, A. F. & Emery, R. J. Acromial morphology: the enigma of the terminology. *Knee. Surg. Sports. Traumatol. Arthrosc.*, 5(4):268-72, 1997.
- Depalma, M. J. & Johnson, E. W. Detecting and treating shoulder impingement syndrome. *Phys. Sportsmed.*, 31(7):25-32, 2003.
- Hallström, E. *Shoulder kinematics and impingement: Dynamic radiostereometric analysis of the shoulder*. Academic Dissertation. Sweden, University of Gothenburg, 2009.
- Hyvönen, P. *On the pathogenesis of shoulder impingement syndrome*. Oulun yliopisto, Oulu University Library, 2003.
- Jobe, C. M. Posterior superior glenoid impingement: expanded spectrum. *Arthroscopy*, 11(5):530-6, 1995.
- Kammer, C. S.; Young, C. C. & Niedfeldt, M. W. Swimming injuries and illnesses. *Phys. Sportsmed.*, 27(4):51-60, 1999.
- McLaughlin, H. L. & Asherman, E. G. Lesions of the musculotendinous cuff of the shoulder. IV. Some observations based upon the results of surgical repair. *J. Bone. Joint. Surg.*, 33(A:1):76-86, 1951.
- Nasca, R. J.; Salter, E. G. & Weil, C.E. *Contact areas of the subacromial joint*. In: Bateman, J. E. & Walsh, R. P. (Eds.). *Surgery of the shoulder*. New York, Dekker, 1984.
- Neer, C. S. 2nd. Anterior acromioplasty for the chronic impingement syndrome in the shoulder. A preliminary report. *J. Bone Joint Surg. Am.*, 54(1):41-50, 1972.
- Neer, C. S. 2nd. Impingement lesions. *Clin. Orthop. Relat. Res.*, (173):70-7, 1983.
- Nirschl, R. P. Rotator cuff tendinitis: basic concepts of pathoetiology. *Instr. Course Lect.*, 38:439-45, 1989.
- Toivonen, D. A.; Tuite, M. J. & Orwin, J. F. Acromial structure and tears of the rotator cuff. *J. Shoulder Elbow Surg.*, 4(5):376-83, 1995.
- Zuckerman, J. D.; Kummer, F. J.; Cuomo, F.; Simon, J.; Rosenblum, S. & Katz, N. The influence of coracoacromial arch anatomy on rotator cuff tears. *J. Shoulder Elbow Surg.*, 1(1):4-14, 1992.

Correspondence to:

Prof. Dr. Frank Silva Bezerra
NUPEB/UFOP Campus Morro do Cruzeiro
Department of Biological Sciences
– Ouro Preto – Minas Gerais – MG
CEP: 35400-170
BRAZIL

Phone: +55 (31) 3559 1694; +55 (31) 3559 1694

Fax: +55 (31) 3559 1680

Email: frank@iceb.ufop.br

Received: 11-04-2012

Accepted: 18-11-2012