



## Hydroalcoholic extract of Brazilian green propolis modulates inflammatory process in mice submitted to a low protein diet



Marina Barcelos de Miranda<sup>a</sup>, Mariana Ferreira Lanna<sup>a</sup>, Ana Luiza Barros Nascimento<sup>a</sup>,  
Carmen Aparecida de Paula<sup>b</sup>, Marcelo Eustáquio de Souza<sup>c</sup>, Mariane Felipetto<sup>d</sup>,  
Lucíola da Silva Barcelos<sup>d</sup>, Sandra Aparecida Lima de Moura<sup>a,\*</sup>

<sup>a</sup> Biomaterials and Experimental Pathology Laboratory, Biological Sciences Department, Federal University of Ouro Preto (UFOP) – Morro do Cruzeiro Campus, 35.400-000, Minas Gerais, Brazil

<sup>b</sup> Clinical Analysis Department, Pharmacy School, Federal University of Ouro Preto (UFOP) – Morro do Cruzeiro Campus, 35.400-000, Minas Gerais, Brazil

<sup>c</sup> Experimental Nutrition Laboratory, Nutrition School, Federal University of Ouro Preto (UFOP) – Morro do Cruzeiro Campus, 35.400-000, Minas Gerais, Brazil

<sup>d</sup> Angiogenesis and Stem Cell Laboratory, Physiology and Biophysics Department, Biological Sciences Institute, Federal University of Minas Gerais (UFMG), Av. Antônio Carlos 6627, 31.270-901, Belo Horizonte, Minas Gerais, Brazil

### ARTICLE INFO

#### Keywords:

Green  
Propolis  
Hydroalcoholic extract  
Inflammation  
Angiogenesis  
Low-protein diet  
Sponge implantation

### ABSTRACT

The occurrence of inflammation and protein malnutrition is an aggravating risk factor for morbidity and mortality in the clinical setting. The green propolis, a natural product made by *Apis mellifera* bees from *Baccharis dracunculifolia* resin, has therapeutic potential to modulate chronic inflammation. However, its effect on inflammation in an impaired nutritional status is not known. The aim of this study was to characterize the effects of the administration of the hydroalcoholic extract of the green propolis in the chronic inflammatory process of mice submitted to a low-protein diet. For this, we used the subcutaneous implantation of sponge disks as an inflammatory model and the animals were distributed in the following groups: standard protein diet (12% protein content), control treatment; standard protein diet, propolis treatment; low-protein diet (3% protein content), control treatment; low-protein diet, propolis treatment. Propolis was given daily at a dose of 500 mg/kg (p.o.) during a period of 7 or 15 days. Our main findings show that animals fed with standard protein diet and treated with propolis had low levels of red blood cells, hemoglobin, and hematocrit, with the subsequent re-establishment of these levels, in addition to monocyte count elevation and higher TNF levels after one week of treatment. In the low-protein diet group, the propolis treatment provided a significant recovery in weight and maintenance of total serum protein levels at the end of two weeks of treatment. Histological analysis showed propolis reduced the inflammatory infiltrate in the sponges of both standard and low-protein diet groups. In addition, the propolis extract presented antiangiogenic effect in both groups. Therefore, our data suggests that the hydroalcoholic extract of the green propolis promotes weight recovery and avoid the reduction of protein levels, in addition to inhibit inflammation and angiogenesis in animals fed with a low-protein diet.

### 1. Introduction

Inflammation is a complex and autoregulated biological process that includes vascular, and cellular components, besides a range of chemical mediators [1]. However, the presence of persistent stimuli may induce continuity of the inflammatory mechanism, resulting in a chronic process [2,3].

Protein deficiency, characterized by low protein intake, reduces plasma amino acid concentrations and weakens the immune system [4,5]. At the same time, extends the inflammatory phase, decreases the

collagen synthesis in fibroblasts, alters angiogenesis and impairs healing by reducing the tensile strength of wounds, limiting the ability of leukocytes to act and increasing the rate of infection [6]. In fact, protein malnutrition aggravates inflammatory diseases [7–9].

The association between nutritional state, inflammatory markers, and the survival of oncological patients have been demonstrated. Malnourished patients have higher concentrations of serum C-reactive protein (CRP) and lymphocytes [10]. Hospitalized patients who receive higher protein intake tend to develop fewer ulcers and have more efficient healing [11]. A recent study found that approximately 33% of

\* Corresponding author.

E-mail address: [sandrilmoura@gmail.com](mailto:sandrilmoura@gmail.com) (S.A.L. de Moura).

<https://doi.org/10.1016/j.bioph.2018.10.116>

Received 19 June 2018; Received in revised form 19 October 2018; Accepted 20 October 2018

0753-3322/ © 2018 Elsevier Masson SAS. This is an open access article under the CC BY-NC-ND license (<http://creativecommons.org/licenses/by-nc-nd/4.0/>).

patients with chronic kidney disease (CKD) have some degree of malnutrition and inflammation, which contribute significantly to the rapid disease progression [12]. Traditional therapies for the treatment of chronic inflammatory diseases have several risks, restrictions and side effects, such as gastrointestinal complications, hemorrhages, heart and renal insufficiency, hypertension, and osteoporosis [13].

The search for alternative medicine and functional foods is a new trend, which has been motivating research on natural compounds and bioactive substances, with the aim of more effective treatments with fewer side effects [14]. It is believed that drug and nutritional therapeutic strategies should be explored in order to complement each other in an attempt to offer treatment, rehabilitation, and wellness. In this context, propolis has been pointed out as an alternative for the treatment of chronic inflammation, as it has evidence of its anti-inflammatory properties in the literature [15,16].

Brazilian green propolis is produced by the Africanized bee *Apis mellifera* and the plant species that supply the resin is *Baccharis dracunculifolia* (Asteraceae), also known as "Alecrim do Campo", a typical Brazilian specie. That is why its color is green [17–19]. Moreover, propolis has the role of modulating the immune system by promoting the reduction of proinflammatory cytokines and the increase of anti-inflammatory ones [20]. The treatment with propolis was able to attenuate the inflammatory response in the colonic mucosa of animals with colitis [21]. Recently, it was also evidenced its action on microRNA that regulates the expression of proteins related to inflammation and wound healing [22]. In addition, animals treated with aqueous green propolis extract had an increase in the expression of the genes associated with the differential activation of macrophages [15].

Faced with the scientific evidence on the anti-inflammatory activities of green propolis, there are still many questions about its effects and the environmental changes that may influence its established outcomes. There is no evidence of the action of green propolis on the inflammatory process in the face of a weakened immune system, which may be caused, for example, by a low-protein diet. In this way, we aimed to evaluate the effects of the hydroalcoholic green propolis extract (HGPE) in the chronic inflammatory response induced by the subcutaneous implant of sponge in an experimental model of protein deficiency.

## 2. Materials and methods

### 2.1. Propolis

The HGPE used in this study is marketed as Cytopropolis® and was provided by the company Pharma Nectar®, located in the city of Belo Horizonte, state of Minas Gerais. This hydroalcoholic extract has a balanced and concentrated combination of the two fractions of green propolis, both alcoholic and aqueous, simultaneously. According to the classification of Brazilian propolis, the extract used in this study belongs to group 12, whose botanical origin is *Baccharis dracunculifolia* (Asteraceae). Its main compounds, characterized by Pharma Nectar®, are Coumaric Acid, Rutin (quercetin-3-O-rutinoside), Pinobanksin, Quercetin, Kaempferol, Apigenin, Pinocembrin, Pinobanksin-3-acetate, Chrysin, Galangin, Techtochrysin, Artepillin C® and Baccharin (Benzenepropanoic acid, 4-[(E)-2-carboxyethenyl]-2-(3-methyl-2-buten-1-yl) phenyl ester).

### 2.2. Animals

Eighty female Swiss mice (6 weeks) were provided by the Laboratory of Experimental Nutrition (LABNEX) from Nutrition School of the Federal University of Ouro Preto. The animals were kept in cages (5 animals per cage) under controlled conditions of temperature (24 °C) and brightness (light/dark cycle of 12 h) with diet and water *ad libitum*. This project was submitted to the Ethics Committee on Animal Use of the Federal University of Ouro Preto (UFOP), being approved under

**Table 1**

Composition of the experimental diets in grams, for each 1000 g of the diet.

Ingredients	Standard protein diet	Low-protein diet
Corn starch	645	735
Casein ( <sup>a</sup> )	120	30
Soy oil	40	40
Sucrose	100	100
Fiber	50	50
Mix of minerals ( <sup>b</sup> )	35	35
Mix of vitamins ( <sup>c</sup> )	10	10

<sup>a</sup> The content of the casein used was 80–90%.

<sup>b</sup> Mineral Mixture: NaCl, HI, MgSO<sub>4</sub> H<sub>2</sub> O, CaCO<sub>3</sub>, MnSO<sub>4</sub> H<sub>2</sub> O, FeSO<sub>4</sub> 0.7H<sub>2</sub> O, CuSO<sub>4</sub> 5H<sub>2</sub> O, CoCl<sub>2</sub> 6H<sub>2</sub> O, KH<sub>2</sub> PO<sub>4</sub>-Reagen.

<sup>c</sup> Vitamin Blend: Retinol acetate, cholecalciferol5, pantoic acid, inositol, riboflavin, thiamine HCL, folic acid, biotin, cyanocobalamin3, α-tocopherol, sucrose q.s. - Merk®.

protocol number 2016/56.

### 2.3. Experimental groups and design

The mice were randomly divided into 4 groups, according to the diets and treatments: 1) Standard protein diet and control treatment (SC); 2) Standard protein diet and HGPE treatment (SP); 3) Low-protein diet and control treatment (LC); 4) Low-protein diet and HGPE treatment (LP). HGPE was given daily during a period of 7 or 15 days. Control treatment groups received vehicle. The euthanasia procedure was performed at the end of each time-point (*i.e.*, at day 7 or 15 after treatment).

### 2.4. Diets

The standard protein diet was composed of 12% of protein, concerning the diet AIN93 M, recommended for rodents [23]. The research team standardized the low-protein diet with 3% of protein. The diets consisted of specific ingredients for rodents, which were weighed, mixed, pelletized and dried at 50 °C for 24 h. The amount of starch in the low-protein diet was adapted to obtain 1 kg of feed (Table 1). Diet and water were offered to animals *ad libitum*. The handmade diets were offered to the animals during the whole experimental period, from the 6th to the 11th week of life (35 days), for the animal groups euthanized 7 days after sponge implantation and from the 6th to the 12th week (42 days) of life for the animal groups euthanized 15 days after implantation.

### 2.5. Sponge implants

In order to mimic the inflammatory process, the subcutaneous implant model of polyester-polyurethane sponge discs (4 mm in diameter, 5 mm thick and 4.64 mg in weight, Vitaform, Manchester UK) was used. The surgical procedure for the preparation and implantation of the sponges followed according to the protocol described by Moura et al. [24]. The implants took place after 4 weeks (28 days) after the beginning of experimental diets, in the 10th week of life, at the same day of beginning the treatment with HGPE.

### 2.6. Treatment

The hydroalcoholic extract of lyophilized green propolis was resuspended in water at a dose of 500 mg / kg, and 200 μl were administered orally (gavage) to the animals of the treated groups, while the animals in the control groups received the same dose of water. The dose of the extract was based on the reference of Moura et al. [25].

## 2.7. Weight changes assessment

The weight of the animals was registered in spreadsheets at the beginning of the experimental period (in the 6th week of life, when the diet administration was started) and on the day of euthanasia. The difference between the final and the initial weight resulted in the weight gained or lost during the whole experimental period. The data were put in Excel®, analyzed in the program Graph Pad Prism 5.0 and expressed in means of weight (g) per group.

## 2.8. Measure of serum proteins

To measure circulating protein levels, blood samples were collected by cardiac puncture, without anticoagulant. The samples were centrifuged for serum separation, which was identified and stored at  $-80^{\circ}\text{C}$ . The total serum protein dosage was determined by the Lowry method [26]. After obtaining the absorbance, the curve was generated and the calculation of the amount of proteins expressed in  $\text{mg}/\mu\text{l}$ . The data were registered and the statistical analysis made in Graph Pad Prism 5.0.

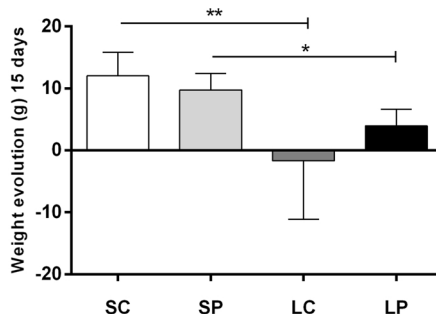
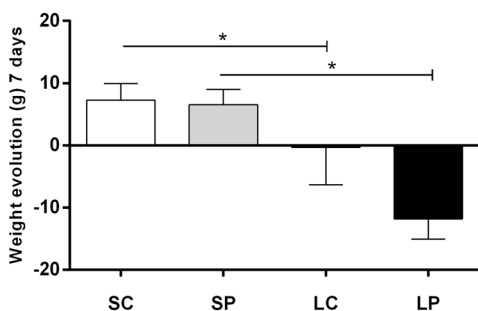
## 2.9. Hematological analysis and blood leucocytes counting

After blood collection by cardiac puncture, the samples were arranged in previously identified microtubes containing 20  $\mu\text{l}$  of EDTA (10%). The tubes containing the blood samples were identified and sent to hematological analysis in the Clinical Analysis Laboratory at School of Pharmacy (LAPAC) in a semiautomatic analyzer (BIOPLUS 200®) using commercial Labtest® kits. The leukogram was performed by manual counting, on slides containing the blood film, stained with May-Grunwald / Giemsa. The analysis was completed with an optical microscope, in a 100-fold objective, using immersion oil.

## 2.10. Histological analysis

After euthanasia, the sponges were removed, placed in cassettes with identification and emerged in formalin solution 10%. For the tissue processing, the sponges were immersed for 30 min in increasing solutions of alcohol (70%, 80%, 90%, 100%), 30 min in xylene for diaphonization and 30 min in paraffin at  $60^{\circ}\text{C}$ . Subsequently, they were included in Paraplast® and the microtomy of the blocks was performed, using a semi-automatic microtome for cuts of  $5\mu\text{m}$  thickness. The staining was performed with hematoxylin and eosin (HE), followed by mounting with coverslips and Entellan® mounting medium. The digital images of the sponges were captured by an optical microscope and camera AmScope 3.0® UCMOS 3000, through software Toup View  $64\times$ .

For the quantitative analysis of the inflammatory infiltrate, the total cells inside the sponges were counted. In the analysis of instability, the variation of the mean values of 20 images/group was achieved by counting cells using the Image J software, version 1.4.3.67. The data were then registered and analyzed using the Graph Pad Prism 5.0 software. The results were expressed as mean number of cells per field.



**Fig. 1.** Average gain and weight loss of the experimental groups with 7 and 15 days of implantation and treatment. In the y-axis are represented the weights in grams (g) and in the x-axis are represented the groups: group Standard protein diet and control treatment (SC); Standard protein diet and HGPE treatment (SP) diet; Low-protein diet and control treatment (LC); Low-protein diet and HGPE treatment (LP). Significant differences between the groups were indicated by one (\*) ( $p < 0.05$ ) or two asterisks (\*\*) ( $p < 0.001$ ).

## 2.11. Quantification of blood vessels

For vessel counting, the minimum number of fields was determined by the study of variation of the mean values instability, in which were obtained vessels count in 5, 10, 15, 20, 25, 30, 35, 40, 45 and 50 randomised fields. According this analysis the variation of the mean values of 40 fields/group were representative for vessel number quantification. The count was then performed using the Image J software and was registered and analyzed using the Graph Pad Prism 5.0 software. The results were expressed as mean of the number of vessels per field.

## 2.12. VEGF and TNF levels

The sponges were removed at the day of euthanasia, weighed, identified and stored at  $-80^{\circ}\text{C}$ . For the dosages, the sponges were homogenized in Drabkin solution. The homogenate was centrifuged at 10,000 g and the supernatant kept at  $-20^{\circ}\text{C}$ . The assays were performed using Kits from R&D systems and according to the manufacturer's instructions. The samples were read in a spectrophotometer at 490 nm. The results were expressed in picograms (pg) of cytokine per milligrams (mg) of tissue.

## 2.13. Statistical analysis

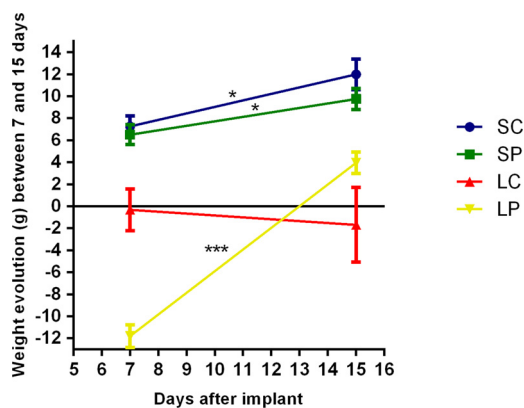
The software Bioestat 5.3 was used to determine the number of animals per group. Statistical analyzes were performed in the program Graph Pad Prism 5.0. The normality test was applied to the data. The *t*-test and the Mann Whitney test were used for independent and non-normal data comparing SC versus SP; LC versus LP; SC versus LC and SP versus LP. The confidence interval considered was 95%, and data were expressed as mean  $\pm$  standard error and number of animals per group. The data were significant when the P value was  $< 0.05$ .

## 3. Results

### 3.1. Body weight

At day 7 post-implantation, the animals fed with the low-protein diet, LC ( $-0.3 \pm 2$ ,  $N = 4$ ) and LP ( $-12 \pm 1$ ,  $N = 4$ ), presented a reduction in body weight, while the animals fed with the standard protein diet, SC ( $7 \pm 1$ ,  $N = 5$ ) and SP ( $7 \pm 0.9$ ,  $N = 5$ ), presented a significant increase in body weight. Interestingly, at day 15 post-implantation, the animals fed with the low-protein diet and treated with HGPE, the LP group ( $4 \pm 1$ ,  $N = 5$ ), presented a significant weight gain when compared with the animals fed with the low-protein diet that received vehicle, the LC group ( $-2 \pm 3$ ,  $N = 5$ ). HGPE had no effect on the body weight of animals fed with the standard protein diet (Fig. 1).

The animals fed with the standard protein diet, SC group ( $12 \pm 1$ ,  $N = 5$ ) and SP group ( $10 \pm 0.9$ ,  $N = 5$ ), have kept gaining weight at day 15 post-implantation when compared with the day 7. Of note, while the LC group had a similar weight loss at both day 15 and day 7



**Fig. 2.** Analysis of mean gain or loss of weight between experimental times of 7 and 15 days of implantation and treatment. The weights were expressed in grams on the y-axis, while the x-axis represents the implantation times (7 and 15 days). Each group is indicated by a line with a corresponding color: group Standard protein diet and control treatment (SC) in blue; Standard protein diet and HGPE treatment (SP) diet in green color; Low-protein diet and control treatment (LC) in red color; Low-protein diet and HGPE treatment (LP) in yellow color. Significant differences between the times were indicated by one (\*) ( $p < 0.05$ ) or three asterisks (\*\*\*) ( $p < 0.0001$ ) (For interpretation of the references to colour in this figure legend, the reader is referred to the web version of this article).

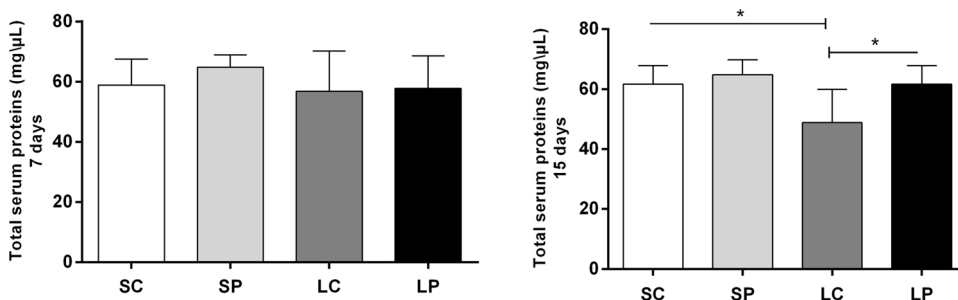
post-implantation, the LP group presented a relevant weight recovery, corresponding to a gain of 15.7 g, at day 15 post-implantation when compared with the day 7 (Fig. 2).

### 3.2. Serum proteins

The results of total serum protein measurement showed no significant difference between the groups at day 7 after sponge implantation (Fig. 3A). However, 15 days after sponge implantation was possible to observe that the LC group ( $49 \pm 4$ ,  $N = 5$ ) presented a reduction in the serum protein levels when compared with the SC group ( $62 \pm 2$ ,  $N = 5$ ). Interestingly, serum protein levels were significantly higher in the group LP ( $62 \pm 2$ ,  $N = 5$ ) when compared with the LC group (Fig. 3), suggesting the HGPE treatment protected the animals fed with the low-protein diet from a reduction in total serum protein levels.

### 3.3. Hematological analysis

At day 7 after implantation, the hematological data of the SP group for erythrocytes ( $6 \pm 0.2$ ,  $N = 5$ ), hemoglobin ( $10 \pm 0.5$ ,  $N = 5$ ), and hematocrit ( $32 \pm 2$ ,  $N = 5$ ) showed a significant reduction when compared with the SC group (Erythrocytes:  $7 \pm 0.1$ ,  $N = 5$ ; Hemoglobin:  $11 \pm 0.2$ ,  $N = 5$ ; Hematocrit:  $37 \pm 0.7$ ,  $N = 5$ ). At day 15, the SP group showed an inversion, in which these same parameters presented an elevation (Erythrocytes:  $7 \pm 0.5$ ,  $N = 4$ ; Hemoglobin:  $11 \pm 0.8$ , Hematocrit:  $37 \pm 3$ ,  $N = 4$ ) when compared with the LP



**Fig. 3.** Dosing of serum proteins from the groups at 7 and 15 days of implantation and treatment. The protein parameters are represented in the y axis and the x axis are arranged in the following groups: Standard protein diet and control treatment (SC); Standard protein diet and HGPE treatment (SP) diet; Low-protein diet and control treatment (LC); Low-protein diet and HGPE treatment (LP). Significant differences ( $p < 0.05$ ) between the times were indicated by asterisks (\*).

group (Erythrocytes:  $5 \pm 0.4$ ,  $N = 5$ ; Hemoglobin:  $8 \pm 0.6$ ,  $N = 5$ ; Hematocrit:  $26.86 \pm 2.369$ ,  $N = 5$ ) (Fig. 4).

The corpuscular volume value of the LC group ( $3 \pm 1$ ,  $N = 4$ ) showed a significant reduction at day 7 post-implantation, when compared with the SC group ( $56 \pm 0.4$ ,  $N = 5$ ). Platelets were elevated in the LP group ( $1397 \pm 135$ ,  $N = 4$ ) when compared with the SP group ( $765 \pm 115$ ,  $N = 5$ ) on the 7th day of implantation (Fig. 4).

### 3.4. Circulating leukocytes

The percentage of blood monocytes in the SP group ( $9 \pm 3$ ,  $N = 5$ ) was significantly higher than in the SC group ( $1 \pm 0$ ,  $N = 5$ ) in the 7th day, but not in the 15th day after sponge implantation. At day 15 after sponge implantation, the LC group ( $2 \pm 1$ ,  $N = 5$ ) showed a low monocyte count when compared with the SC group ( $7 \pm 1$ ,  $N = 5$ ) and the LC group ( $5 \pm 2$ ,  $N = 5$ ) showed a significant reduction in the percentage of blood neutrophils when compared with the SC group ( $28 \pm 8$ ,  $N = 5$ ). In contrast, there was an increase in the percentage of lymphocytes in the LC group ( $77 \pm 8$ ,  $N = 4$ ) when compared with the SC group ( $62 \pm 9$ ,  $N = 5$ ) 15 days after sponge implantation (Fig. 5).

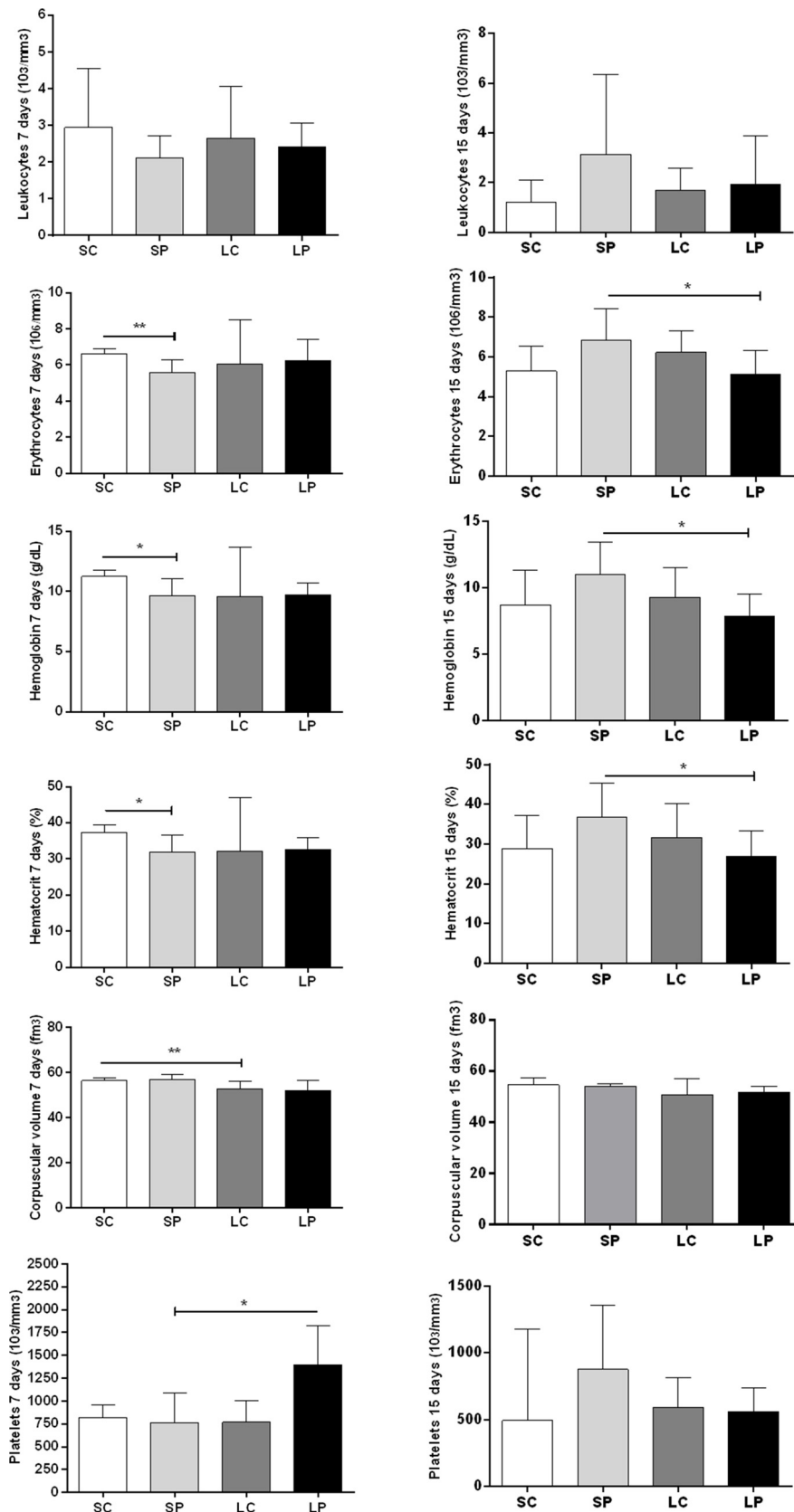
### 3.5. Sponge histological analysis

The Fig. 6 shows the histological changes of the sponges at day 7 (A–D) and day 15 (E–H) post-implantation. It is observed a progressive increase of inflammatory infiltrate, composed of polymorphonuclear cells, macrophages and lymphocytes, diffusely distributed throughout the matrix, with a higher concentration in the conjunctive capsule structured at the periphery of the sponges. The formation of a fibrovascular stroma, composed of thin extracellular matrix fibers and fibroblasts, was observed in both time-points. At day 15 after implantation, it is observed a predominance of macrophages, when compared with the sponges harvested 7 days post-implantation. In the sponges from animals fed with a low-protein diet (LC and LP), a larger number of vessels was observed at day 7 post-implantation when compared with the standard protein diet groups. Even more vessels were observed in the control groups SC (Fig. 6E) and LC (Fig. 6G) at day 15 post-implantation.

The quantitative analysis of the inflammatory infiltrate into the sponges (Fig. 7) showed that, at day 7 post-implantation, the SP ( $184 \pm 18$ ,  $N = 5$ ) and LP ( $169 \pm 29$ ,  $N = 5$ ) groups presented lower inflammatory infiltrate when compared with its control groups that received vehicle, the SC ( $234 \pm 16$ ,  $N = 5$ ) and LC ( $277 \pm 28$ ,  $N = 5$ ) groups, suggesting the HGPE treatment exerts an anti-inflammatory effect independent on the nutritional status of the animals. At day 15, the LP group ( $313 \pm 26$ ,  $N = 5$ ) showed raised levels of inflammatory infiltrate compared to the SP group ( $213 \pm 18$ ,  $N = 5$ ).

### 3.6. Angiogenesis assessment

The counting of vessels in the sponge's microenvironment allows the analysis of the angiogenic process. After 7 days of implantation, the groups fed with a low-protein diet (LC:  $0.3 \pm 0.1$ ; LP:  $0.6 \pm 0.2$ )



**Fig. 4.** Hematological analysis of the animals, indicating: leukocytes; erythrocytes; hemoglobin, hematocrits; corpuscular volume and platelets with 7 and 15 days of implantation and treatment. The haematological parameters are represented in the y axis and the x axis are arranged in the following groups: group Standard protein diet and control treatment (SC); Standard protein diet and HGPE treatment (SP) diet; Low-protein diet and control treatment (LC); Low-protein diet and HGPE treatment (LP). Significant differences between the groups were indicated by one (\*) ( $p < 0.05$ ) or two asterisks (\*\*) ( $p < 0.001$ ).

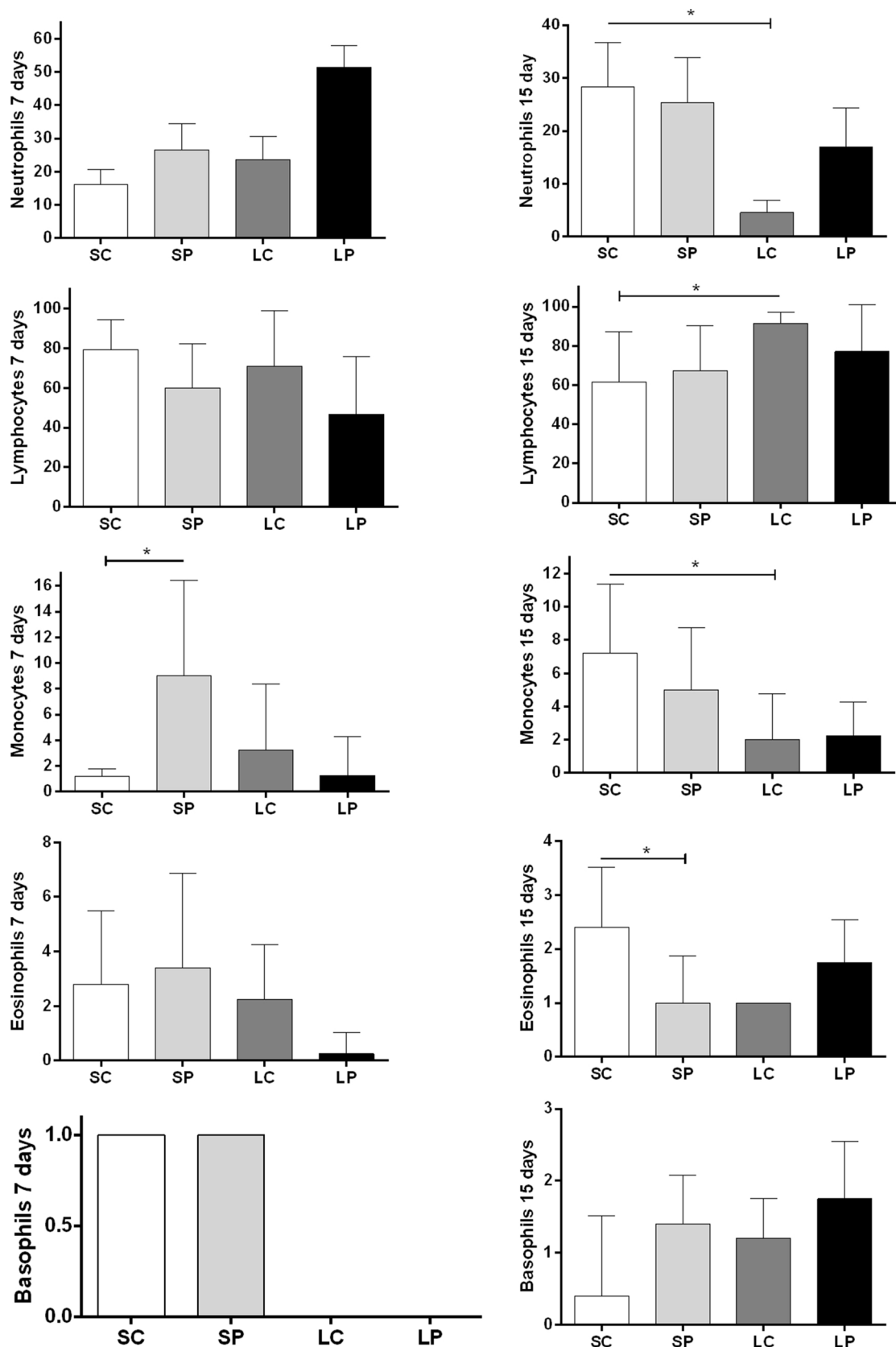
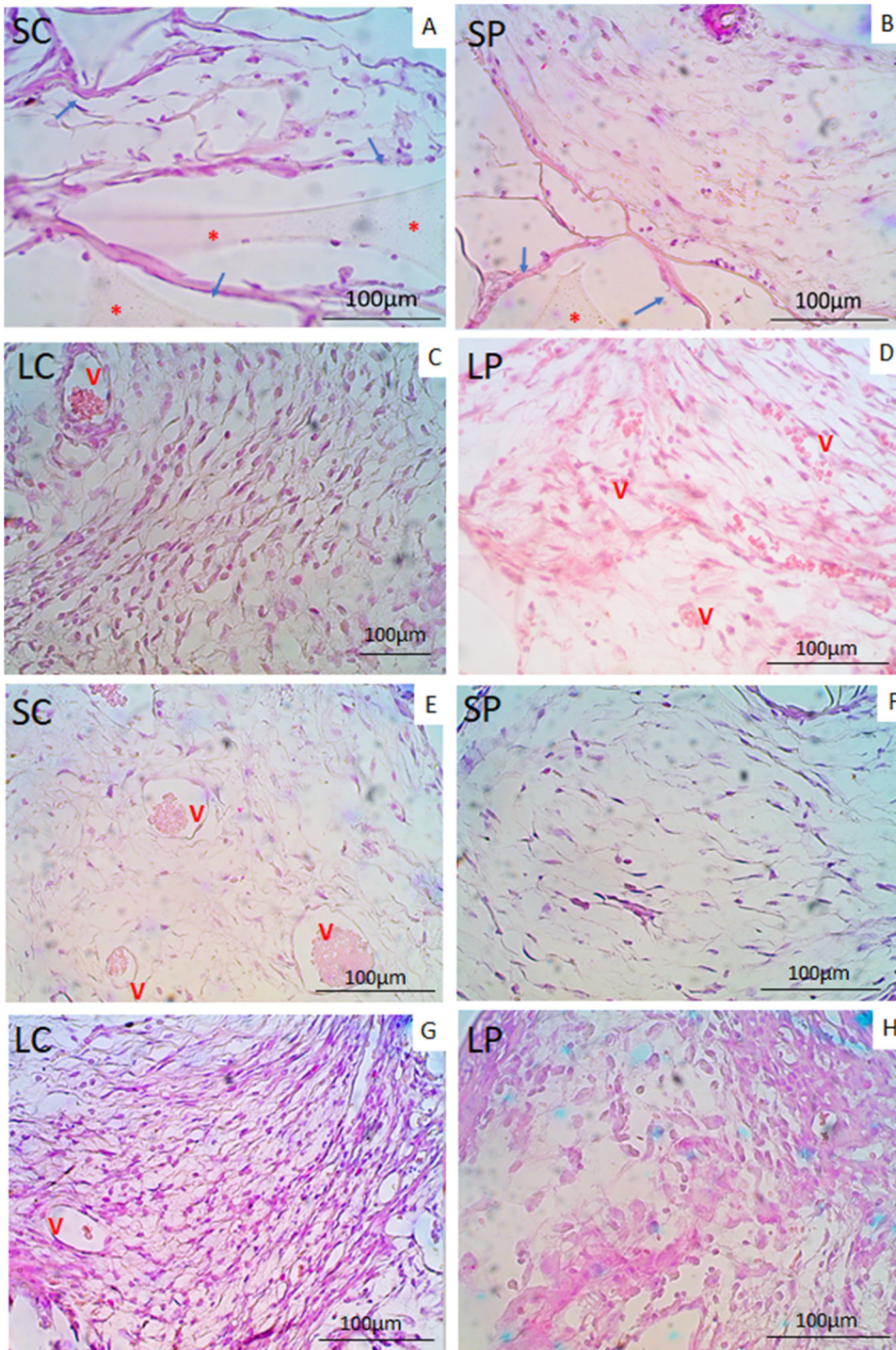
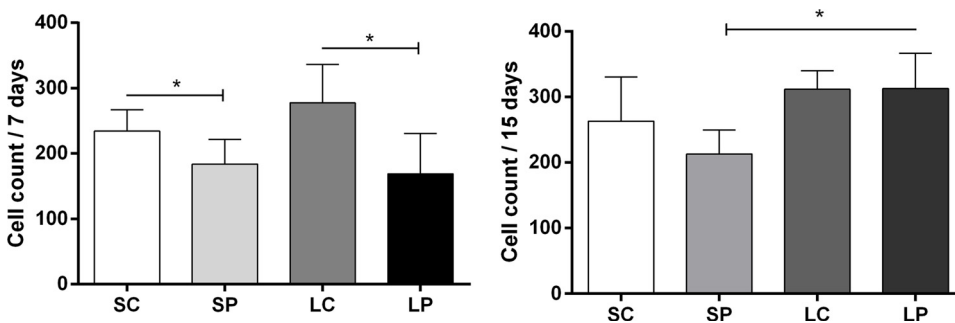


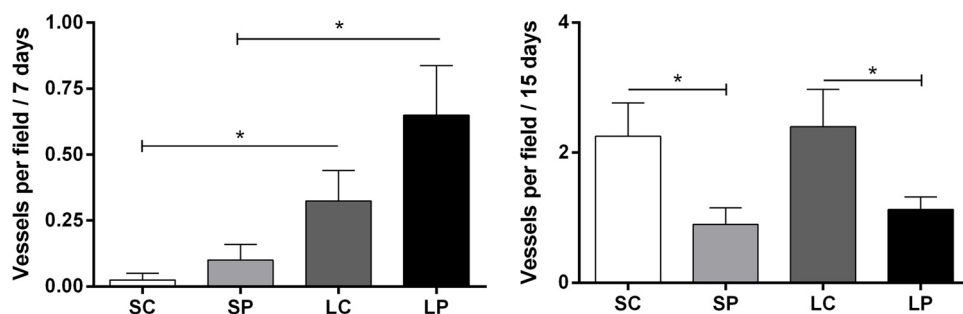
Fig. 5. Relative differential count of leukocytes, performed by manual counting in the blood smears, indicating respectively: neutrophils; lymphocytes; monocytes; eosinophils and basophils, with 7 and 15 days of implantation, respectively. The parameters of the leukogram are represented on the y axis and on the x axis are arranged the groups: group Standard protein diet and control treatment (SC); Standard protein diet and HGPE treatment (SP) diet; Low-protein diet and control treatment (LC); Low-protein diet and HGPE treatment (LP). Significant differences between the groups were indicated by asterisks (\*) ( $p < 0.05$ ).



**Fig. 6.** Histological sections of 5  $\mu$ m, stained in HE, representative of sponge implants, after 7 and 15 days of implantation. The photomicrographs (6A-H) represent groups with 7 days of implantation: Standard protein diet and control treatment (SC) in A; Standard protein diet and HGPE treatment (SP) diet in B; Low-protein diet and control treatment (LC) in C; Low-protein diet and HGPE treatment in D; and groups with 15 days of implantation: Standard protein diet and control treatment (SC) in E; Standard protein diet and HGPE treatment (SP) diet in F; Low-protein diet and control treatment (LC) in G; Low-protein diet and HGPE treatment in H. The highlights show sponges in A and B (red asterisk); collagen fibers in A and B (blue arrow); and blood vessels in C, D, E and G (letter "v" in red). The images were taken in a 40x magnification (For interpretation of the references to colour in this figure legend, the reader is referred to the web version of this article).



**Fig. 7.** Cell count inside the sponge implants, with the help of Image J. Image expressed in average number of photos per field. In the y-axis are represented the averages of the cell count and in x the groups are represented: group Standard protein diet and control treatment (SC); Standard protein diet and HGPE treatment (SP) diet; Low-protein diet and control treatment (LC); Low-protein diet and HGPE treatment (LP). Significant differences between the groups were indicated by one asterisks (\*) ( $p < 0.05$ ).



**Fig. 8.** Vessel count of sponges collected after 7 and 15 days of implantation. Average counts of vessels per field. In the y-axis are represented the means of the number of vessels per field and in the x-axis are represented the groups: Standard protein diet and control treatment (SC); Standard protein diet and HGPE treatment (SP) diet; Low-protein diet and control treatment (LC); Low-protein diet and HGPE treatment (LP). Significant differences between the groups were indicated by one (\*) ( $p < 0.05$ ) or two asterisks (\*\*) ( $p < 0.001$ ).

showed a significant increase in the number of vessels, when compared with the groups fed with a standard-protein diet (SC:  $0.02 \pm 0.0$ , SP:  $0.1 \pm 0.0$ ). After 15 days of implantation, however, it was observed a significant reduction in the number of vessels in the groups treated with the HGPE (SP:  $0.9 \pm 0.2$ ; LP:  $1 \pm 0.2$ ), when compared with the control groups that received vehicle (SC:  $2 \pm 0.5$ ; LC:  $2 \pm 0.5$ ) (Fig. 8).

### 3.7. VEGF and TNF levels in the sponges

The determination of vascular endothelial growth factor (VEGF) levels 7 days post-implantation (Fig. 9) demonstrated that there were no significant differences between the assessed groups. However, after 15 days of implantation, higher VEGF levels were observed in the SP ( $283 \pm 18$ ,  $N = 5$ ) group, in comparison to the SC ( $184 \pm 46$ ,  $N = 5$ ) group (Fig. 9). The tumor necrosis factor alpha (TNF) analysis, in turn, showed that the SP group ( $221 \pm 51$ ,  $N = 3$ ) exhibited a significant elevation in TNF levels when compared with the SC group ( $28 \pm 3$ ,  $N = 3$ ) after 7 days of implantation (Fig. 10).

## 4. Discussion

Similar to our results about the changes in body weight (Fig. 5), Araújo et al. [27] found an interruption in body weight gain and significant weight loss when investigating the action of protein deficiency on the mesenteric plexus and descending colon of young rats, with a 4% protein diet, offered for 12 weeks. Since body weight is a simple measure of the total mass of the body components and a data strongly consolidated in studies involving nutritional analysis [28,29], we can affirm the effectiveness of the low-protein diet in this study in producing a nutritional insult.

A better analysis of the effect of HGPE on the weight parameter was considered, and a comparative analysis of the weight gain between the groups was performed, from the 7th to the 15th day of implantation and treatment (Fig. 2). This data showed the ability of weight recovery in the LP group and the effect of the hydroalcoholic extract of the green propolis on this parameter. These results resemble those of Gheisari et al. [30], who studied the effects of ethanolic extract green propolis as an alternative to the growth promoter antibiotics used in chickens, using the doses of 50, 100, 200 and 300 mg/kg of propolis ethanolic

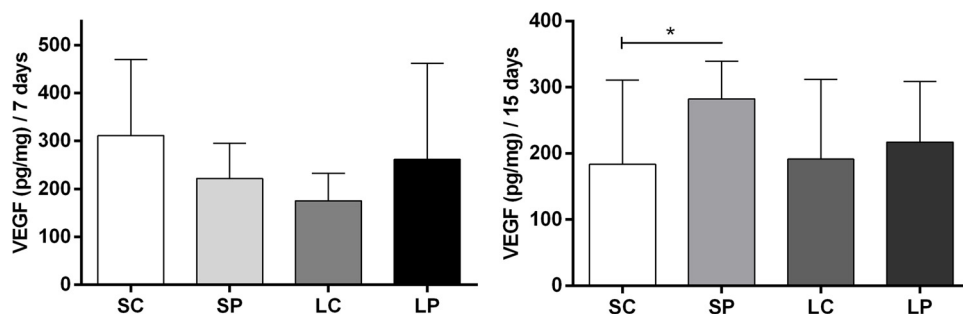
extract for 42 days. The results of this work showed that propolis increased the body weight of the chickens and stimulated the daily intake of the animals when compared to the control group [30].

The serum protein dosage reflects essential information. On the 7th day of implantation, there were no significant differences between the groups regarding serum protein values (Fig. 3), giving similarities to the results of Quereshi and Quereshi [31], in which after submitting rats to protein malnutrition for 3–6 weeks, only showed changes in serum levels of albumin after prolonged malnutrition. From the time of 15 days (Fig. 3) LC group kept a reduction in serum levels of total proteins and, interestingly, the LP group showed maintenance in these levels. These findings allow us to make assumptions about the ability of HGPE to interfere in the total serum protein profile. This hypothesis is supported for Batista et al. [32], which demonstrate the role of propolis in the modification of the protein profile after the 10th day of treatment. These authors state that such effect is dose-dependent and may vary according to the dose of the treatment. In this same way, Ferraz et al. [33] reported that the amount of propolis offered to animals could influence the quantification of total serum proteins.

It is important to note that the action of propolis in the SP group induced an increase in erythrocytes, hemoglobin, and hematocrit on the 15th day (Fig. 4), even though on the 7th day (Fig. 4), the same group had presented these rates reduced. These dynamics were also reported by Ferraz et al. [33] that assessed the effects of green propolis on hematological parameters of marmoset monkeys. The animals treated with 5% propolis had the levels of erythrocytes and hematocrits reduced at the first moment of the study, and after a second moment, these same rates were elevated. In the LP group, due to protein malnutrition, a deficit of these indices is expected [33]; in addition, the treatment with HGPE was not able to alter this profile.

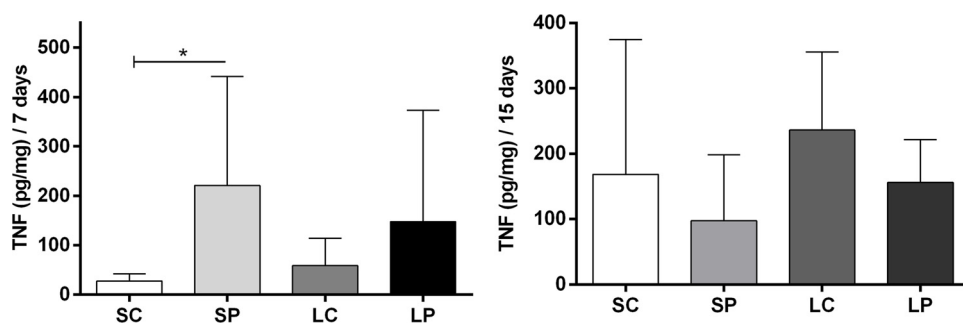
The values for mean corpuscular volume, neutrophils, and lymphocytes showed significant differences only between the SC and LC groups, indicating that only the diet affected these parameters (Figs. 4 and 5). The neutrophil and lymphocyte data (Fig. 5) further indicate that the inflammatory process triggered by the subcutaneous implantation of the sponge discs was able to induce medullary changes, recruit cells and induce an inflammatory response, but with less efficiency in groups submitted to a low-protein diet.

The quantification of platelets from the LP group (Fig. 4) was elevated on the 7th day, compared to the SP group, evidencing the action



**Fig. 9.** Evaluation of VEGF production of sponges at 7 and 15 days after implantation and treatment. Cytokine quantification was expressed in pg / mg on the y-axis, while the groups were represented on the x-axis: Standard protein diet and control treatment (SC); Standard protein diet and HGPE treatment (SP) diet; Low-protein diet and control treatment (LC); Low-protein diet and HGPE treatment (LP). Significant differences ( $p < 0.05$ ) between the groups were indicated by asterisks (\*).





**Fig. 10.** Evaluation of TNF- $\alpha$  production in implants withdrawn at times of 7 and 15 days post implantation. The cytokine quantification was expressed in picograms pg / mg on the y-axis, while the groups were represented on the x-axis: Standard protein diet and control treatment (SC); Standard protein diet and HGPE treatment (SP) diet; Low-protein diet and control treatment (LC); Low-protein diet and HGPE treatment (LP). Significant differences ( $p < 0.05$ ) between the groups were indicated by asterisks (\*).

of the HGPE on this parameter, in the assessed model. Platelets play an essential role in the coagulation processes and the inflammatory response, through the activation and release of growth factors, such as platelet-derived growth factor (PDGF), which plays an important role in the vascular phase, mainly in the synthesis of prostaglandins and leukotrienes [34].

Results from Batista et al. [32], on the role of propolis in the leukocyte response, showed that treatment with the highest dose of propolis (800  $\mu$ l - 10%) increased the number of leukocytes comparing the control group and those treated with lower doses. This increase was due to an increase in the number of lymphocytes. However, we did not find any significant changes in the quantification of total leukocytes in animals treated with HGPE in both studied times (Fig. 4). On the 7th day of implantation, the quantification of monocytes in the SP group was higher when compared to the SC group (Fig. 5E). According to Orsolich and Basic [35], propolis has properties that increase the macrophage population in rats, due to its phenolic compounds [36], which would explain such findings. On the 15th day of implantation, the LC group had a low number of monocytes, compared to the SC group. These results indicate that HGPE exerted activity on monocyte cell recruitment in an early stage (Fig. 5). Similar to our results, Moura et al. [24] demonstrated that the aqueous extract of green propolis is capable of recruiting macrophages selectively in the sponge implant model, accelerating the tissue repair process. Also in this way, Lima et al. [15] reported the power of green propolis, in the same experimental model of sponge implant, to increase in 23 times the activation of markers associated with the activation of macrophages through the classical pathway, and in 8 times the alternative activation. They also showed a remarkable increase in the expression of the genes associated with differential activation of macrophages. The LP group showed no change in the number of monocytes, as observed in the SP group, indicating that the diet may have influenced this cellular profile. Protein deficiency results in impaired cell production, which spoils immunity and the inflammatory process [37].

The number of eosinophils on the 7<sup>th</sup> day of implantation (Fig. 5G) showed that these cells are elevated in the SP group, compared to LP. On the 15th day (Fig. 5H) there was a reversal of this profile, with reduction of this parameter in the SP group, compared to the SC. Thus, it is possible to infer that HGPE increased the recruitment of these cells on the 7<sup>th</sup> day. The eosinophils act in the pathogenesis of allergic reactions and infections by endogenous parasites [33]. This finding differs from the study by Ferraz et al. [33], which did not find alterations in this cellular type of marmoset monkeys treated with green propolis. However, Orsi and Siqueira [38] found a relationship between the administration of propolis in parrots and the increase of eosinophils, conferring immunomodulatory properties to propolis. Such differences may be explained by several factors, such as the animal specimen, the dose and type of the propolis extract administered, the time of treatment and the experimental model. These same variations justify in part the great contrast in the literature about the different profiles of the inflammatory response under the influence of the treatment with propolis extracts. However, the present work demonstrated the influence of nutritional status on the establishment of an efficient inflammatory

response and revealed that propolis contributed significantly to an improvement of this profile. Some of the hematological parameters of this study still need the greater support of the literature for comparisons and knowledge about the mechanisms of action of the green propolis and more robust conclusions. New experimental studies need to be made with the objective of determining the influence of green propolis on hematological parameters of mice.

The polyurethane polyester sponge disc subcutaneous implant model (Vitaform Ltd., Manchester, UK) was efficient in inducing a chronic inflammatory response, as already reported in other studies that used the same inflammatory model. The implantation of the discs produced a compartmentalized microenvironment, and its porosity allowed the infiltration of inflammatory cells, fibroblasts and the formation of blood vessels in its interior [24,39]. In a similar way to what is presented in the literature, the sponges were well tolerated by the animals, and there was no evidence of pain and discomfort in the animals during the experimental period [24]. Histological analysis at both times (Fig. 6) showed more intense inflammation in the groups with a low-protein diet (LC and LP), which can be explained by the low amount of casein in the diet, since this is responsible for the low concentrations of amino acids in plasma, thus weakening the immune system [5]. The cell count inside the sponges showed that, at 7 days (Fig. 7), there was a significant decrease in the inflammatory infiltrate in the groups treated with HEGP.

Similarly, at the time of 15 days, a reduction of the inflammatory infiltrate in the SP group could be seen. Thus, we observed that green propolis was able to maintain a low inflammatory infiltrate in both treated groups, in the time of 7 days, not being able to maintain these levels in the organism with protein malnutrition, in the time of 15 days (Fig. 7). The reduction of the inflammatory infiltrate in the sponge matrix of the group SP is in agreement with the modulatory activity exerted by the propolis, already described in other published works [15,21,24], although they did not use a green propolis extract with the same composition, reinforcing the anti-inflammatory action of the green propolis in the studied model and the inflammatory process.

Gonçalves et al. [21], for example, assessed the therapeutic effect of rectal administration of alcoholic extract of green propolis in rats submitted to experimental colitis and euthanized after 7 and 14 days of colitis induction. In this study, green propolis extract decreased the number of cysts, abscesses, and inflammatory infiltrate in the colon [21]. Such findings resemble our histological and nucleate counts. The data presented here represent the target profile of the inflammatory response in the different evaluated groups. Thus, both the low-protein diet and the administration of HEGP were able to influence the inflammatory response profile. Such findings still reinforce the important role of HEGP in the modulation of inflammatory kinetics. The studies of Lima et al. [15] and Moura et al. [25] used an aqueous extract of different composition of the hydroalcoholic extract used in the present study and yet they showed many similarities with respect to our findings, reinforcing the anti-inflammatory action of the green propolis in the studied model and the inflammatory process. Despite the difference of the composition between the propolis used in our study, with the propolis used in other studies, we verified that its biological actions are

compatible. It is also reported that the biological actions of propolis are due to the synergism of its various components, not the isolated action of some of its compounds, as mentioned by Pereira et al. [40]. However, some differences are found between studies with propolis, which can be justified by differences between studies, such as methodology, animal model, doses, concentration and composition of propolis.

It is known that angiogenesis consists of the neovascularization process from preexisting blood vessels, being controlled by a balance between pro and anti-angiogenic molecules ([41,42]). It is closely related to chronic inflammation [43] since it is responsible for the transport of inflammatory cells to the site of inflammation along with transport of nutrients and oxygen [44]. The subcutaneous sponge implant model allows the assessment of the kinetics of inflammatory angiogenesis through qualitative and quantitative studies [39].

The vessel count at 7 days of implantation (Fig. 7) showed that the groups submitted to a low-protein diet (LC and LP) had a higher number of blood vessels when compared to that groups with a standard-protein diet (SC and SP). In the 15-day period (Fig. 7), a smaller number of vessels were observed in the groups treated with HEGP (SP and LP), demonstrating the antiangiogenic action of green propolis, more evident in the time of 15 days of implantation, regardless of nutritional status. The antiangiogenic activities of propolis may contribute to its anti-inflammatory effects [19]. It is important to note that, on the 7th day of implantation, the inflammation was more intense in the groups with a low-protein diet. As already discussed, a more intense inflammatory process requires a greater nutritional intake, and therefore, a greater vascularization and neoangiogenesis, in order to establish greater blood, oxygen and nutrients supply to the inflamed tissue (Fig. 7). The antiangiogenic action of propolis was also evidenced in other studies, such as Lima et al. [15] which investigated the effect of the aqueous extract of green propolis at 500 mg/kg on inflammation, angiogenesis, and fibrogenesis in the synthetic sponge model implanted in the mice's abdomen. In this study, propolis was able to induce an increase in peritoneal vascular permeability, showed anti-inflammatory and antiangiogenic activity, being verified by the reduction in the focal levels of TGF- $\beta$ 1 and by the determination of the hemoglobin content in the implanted sponge compartment [15].

VEGF is a glycoprotein related to angiogenesis. It can promote the growth of endothelial cells derived from arteries and veins, with hypoxia as the primary stimulus. It is one of the most important factors for the increase in the number of vessels in the inflammatory process [19]. Our findings showed an increase in VEGF in the group treated with HEGP and submitted to the standard protein diet (SP), on the 15th day of implantation (Fig. 9), corroborating with other studies that similarly demonstrated the action of propolis on this cytokine [19,24]. Moura et al. [24] suggested that the elevation of VEGF by the green propolis occurs as an adaptive response to the antiangiogenic action of propolis. In their study, the results showed that the animals treated orally with the aqueous extract of green propolis (500 mg / kg) during ten days presented a higher production of this cytokine. However, treatment with HEGP was not able to induce a similar response in the low-protein diet (LP) group.

Our findings indicated a significant increase in cytokine TNF levels in the sponges of the SP group compared to the SC group (Fig. 10), on the 7<sup>th</sup> day after implantation. These results corroborate with the findings of Lima et al. [15], who similarly used the inflammatory model of sponge implant and performed oral administration of green propolis [15]. It is worth comparing that this same group (SP), which presented an increase in TNF cytokine production at 7 days, also showed an increase in the number of monocytes on the 7<sup>th</sup> day after implantation (Fig. 5). Circulating monocytes differentiate into macrophages and, among their various functions, coordinate the production of pro-inflammatory cytokines, among which TNF [1]. Induction for the production of this proinflammatory cytokine cannot be confused with its unregulated synthesis, which is presented in chronic inflammatory diseases such as Crohn's disease and psoriasis [45]. The stimulus for the

production of TNF by macrophages is due to the action of propolis in promoting the resolution of the inflammatory process predictably, as it was verified in the time of 7 days, through the recruitment of macrophage from different populations, selectively. Moura et al. showed the same result [24] in which an elevation of TNF levels was reported on the 7th day of implantation. However, on day 14, these levels were reduced in the treated group and elevated in the control group. This study demonstrates that propolis acted in the maintenance of a regulated inflammatory profile [24], corroborating with the data achieved in the present study. In time, this study states that the low-protein diet influenced the secretory profile of this cytokine (TNF), despite the administration of HGPE.

## 5. Conclusion

The experimental model of protein deficiency influenced the weight and serum protein levels of the animals. The subcutaneous sponge disc implant effectively induced the inflammatory process, allowing its assessment under the proposed nutritional conditions. The hydroalcoholic extract of green propolis promoted weight recovery and maintenance of total serum protein levels in animals submitted to a low-protein diet. Although the low-protein diet interfered with the circulating cell medullary response pattern, HEGP selectively altered the hematological and leukocyte parameters in the treated groups, increasing monocyte recruitment early in the groups treated with propolis. In the model assessed, the treatment with HEGP still exerted a modulatory action in the inflammatory kinetics, even in those groups submitted to a low-protein diet, but did not obtain the same efficiency in these models as in the standard-protein diet. The antiangiogenic action of HEGP was also evidenced, regardless of nutritional status. Thus, we demonstrate in this study the great potential of the hydroalcoholic extract of green propolis as an alternative, used in a complementary way in the existing therapies for the treatment of chronic inflammatory diseases, even in states of protein malnutrition.

## Conflict of interests

All authors confirm the absence of conflicts of interest with the publication of this article.

## Financial support

Foundation for research support of Minas Gerais (FAPEMIG) (APQ 02218-13); Higher Education Personnel Improvement Coordination (CAPES).

## Acknowledgments

We thank the Laboratory of Experimental Nutrition (LABNEX) - School of Nutrition (ENUT / UFOP) for help and support with the experimental model; to the company Pharma Nectar®, which kindly yielded the hydroalcoholic extract of the green propolis (Cytopropolis®) used in this study; to the Laboratory of Clinical Analysis (LAPAC), of the School of Pharmacy for the support in the hematological analyzes; to development agencies Foundation for research support of Minas Gerais (FAPEMIG) (APQ 02218-13) and Higher Education Personnel Improvement Coordination (CAPES), for financial support.

## References

- [1] A.K. Abbas, A.H. Lichtman, *Cellular and Molecular Immunology*, 6th ed, Saunders, 2003.
- [2] W.D.M. Cruvinel, D. Mesquita Jr., J.A. Araújo, T.T. Catelan, A.W. De Souza, N.P. Da Silva, L.E. Andrade, *Fundamentals of innate immunity with emphasis on molecular and cellular mechanisms of inflammatory response*, Bras. J. Rheumatol. 50 (n. 4) (2010) 434–461.
- [3] A.C.L. Campos, A. Borges-Branco, A.K. Groth, *Wound healing*, Arq. Bras. Cir. Dig.

- 20 (1) (2007) 51–58.
- [4] A. Fechner, C.C. Bohme, S. Gromer, M. Funk, R.H. Scirmer, K. Becker, Antioxidant status and nitric oxide in the malnutrition syndrome Kwashiorkor, *Pediatr. Res.* 49 (n. 2) (2001) 237–243.
- [5] G. Wu, N.E. Flynn, S.P. Flynn, C.A. Jolly, P.K. Davis, Dietary protein or arginine deficiency impairs constitutive and inducible nitric oxide synthesis by young rats, *J. Nutr.* 129 (n. 7) (1999) 1347–1354.
- [6] R.L. Ruberg, Role of nutrition in wound healing, *Symp. Wound Manag.* 64 (n. 4) (1984) 705–714.
- [7] L.V.D.S. Prado, E.M.C.S. Santos, M.C.L. Luz, P.M.C.D.S. Silva, P.C.F.P. Gadelha, Inflammation, and malnutrition in a renal replacement therapy unit of Northeastern Brazil, *Nutr. Clín. Diet. Hosp.* 34 (3) (2014) 29–36.
- [8] L.J. Curtis, P. Bernier, K. Jeejeebhoy, J. Allard, D. Duerksen, L. Gramlich, M. Laporte, H.H. Keller, Costs of hospital malnutrition, *Clin. Nutr.* (2016).
- [9] U.E. Schaible, S.H.E. Kaufmann, Malnutrition and infection : complex mechanisms and global impacts, *PLoS Med.* 4 (n. 5) (2017) 1–11.
- [10] C.S.Y. Tan, J.A. Read, V.H. Phan, P.J. Beale, J.K. Peat, S.J. Clarke, The relationship between nutritional status, inflammatory markers and survival in patients with advanced cancer : a prospective cohort study, *Support. Care Cancer* 23 (2015) 385–391.
- [11] R.J. Stratton, Elucidating effective ways to identify and treat malnutrition. N. November, *Proc. Nutr. Soc.* (2005) 305–311.
- [12] D. Jagadeswaran, E. Indhumathi, A.J. Hemamalini, V. Sivakumar, P. Soudararajan, M. Jayakumar, Inflammation and nutritional status assessment by malnutrition-inflammation score and its outcome in pre-dialysis chronic kidney disease patients, *Clin. Nutr.* 5614 (n. 18) (2018) 35–36.
- [13] L.M.H. Mota, B.A. Cruz, C.V. Brenol, D.F. Pollak, G.R.C. Pinheiro, I.M.M. Laurindo, I.A. Pereira, J.F. Carvalho, M.B. Bertolo, M.M. Pinheiro, M.V.C. Freitas, N.A. Silva, P. Louzada-Júnior, P.D.S. Barros, R.D.N.G. Giorgi, R.A.C. Lima, L.E.C. Andrade, Safe use of biological therapies for the treatment of rheumatoid arthritis and spondyloarthritis, *Rev. Bras. Reumatol.* 5 (55) (2015) 281–309.
- [14] C. Raud, Functional foods: the new frontier of the food industry, *Rev. Soc. Polít.* 16 (31) (2008) 85–100.
- [15] L.D.C. Lima, S.P. Andrade, P.P. Campos, L.S. Barcelos, F.M. Soriani, S.A.L. Moura, M.A.N.D. Ferreira, Brazilian green propolis modulates inflammation, angiogenesis and fibrogenesis in intraperitoneal implant in mice, *BMC Complement. Altern. Med.* 14 (2014) 1–9.
- [16] P. Montpied, F. Bock, G. Rondouin, G. Niel, L. Briant, A.S. Courseau, M.L. Natoli, J. Bockaert, Caffeic acid phenethyl (CAPE) prevents inflammatory organotypic hippocampal slice cultures, *Mol. Brain Res.* 115 (2003) 110–120.
- [17] E.L. Ghisalberti, Propolis: a review, *Bee World* 60 (n. 2) (1979) 59–84.
- [18] A. Salatino, E.W. Teixeira, G. Negri, D. Message, Origin and chemical variation of Brazilian Propolis, *eCAM 2* (February) (2005) 33–38.
- [19] Y.S. Song, E.H. Park, K.J. Jung, C. Jin, Inhibition of angiogenesis by propolis, *Arch. Pharm. Res.* 25 (n. 4) (2002) 500–504.
- [20] J.L. Machado, A.K.M. Assunção, M.C.P.S. Silva, A.S. Reis, G.C. Costa, D.S. Arruda, B.A. Rocha, M.M.O.L. Vaz, A.M.A. Paes, R.N.M. Guerra, A.A. Berretta, F.R.F. Nascimento, Brazilian green propolis: anti-inflammatory property by an immunomodulatory activity, *Evid. Based Complement. Altern. Med.* 2012 (2012).
- [21] M. Gonçalves, L. Hernandez, C.A.B. Amado, S.L. Franco, J.F.S. Silva, M.R.M. Natali, Use of Propolis hydroalcoholic extract to treat colitis experimentally induced in rats by 2,4,6-trinitrobenzenesulfonic acid, *Evid. Bas. Comp. Altern. Med.* (2013).
- [22] V. Zaccaria, V. Curti, A.D. Lorenzo, A. Baldi, C. Maccario, S. Sommati, R. Macchi, M. Daglia, Effect of green and brown Propolis extracts on the expression levels of microRNAs, mRNAs and proteins, related to oxidative stress and inflammation, *Nutrients* 9 (1090) (2017).
- [23] P.G. Reeves, F.H. Nielsen, G.C. Fahey Júnior, AIN-93 Purified Diets for Laboratory Rodents: Final Report of the American Institute of Nutrition Ad Hoc Writing Committee on the Reformulation of the AIN-76A Rodent Diet, American Institute of Nutrition, 1993.
- [24] S.A.L. Moura, G. Negri, A. Salatino, L.D.C. Lima, L.P.A. Dourado, J.B. Mendes, S.P. Andrade, M.A.N.D. Ferreira, D.C. Cara, Aqueous extract of Brazilian green propolis: Primary components, evaluation of inflammation and wound healing by using subcutaneously implanted sponges, *Evid. Based Complement. Altern. Med.* 2011 (2011).
- [25] S.A.L. Moura, M.A.N.D. Ferreira, S.P. Andrade, M.L.C. Reis, M.L. Noviello, D.C. Cara, Brazilian green propolis inhibits inflammatory angiogenesis in a murine sponge model, *Evid. Based Complement. Altern. Med.* 2011 (2011).
- [26] O.H. Lowry, N.J. Rosebrough, A.L. Farr, R.J. Randall, Protein measurement with the Folin phenol reagent, *J. Biol. Chem.* 193 (1951) 265–275.
- [27] E.J.A. Araújo, D.M.G. Sant'anam, S.L. Molinari, M.H.M. Neto, Quantitative study of the myenteric plexus of the descending Colon of young rats subjected to intense protein deficiency, *Int. J. Morphol.* 24 (n. 4) (2006) 591–597.
- [28] Nascimento, O. J. M; Madi, K; Silva, J. B. G; Filho, P. J; Hahn, M. D Couto, Considerations about the striate muscle in protein deprivation: an experimental study in albino rats. *Arq Neuro Psiquiat*, 48, 4, 395-402, 1990.
- [29] E.M. Silva, L.M. Oliveira, S.S. Almeida, *Braz. J. Behav. Anal.* 10 (2) (2014) 165–174.
- [30] A. Gheisari, S. Shahrvand, N. Landy, Effect of ethanolic extract of propolis as an alternative to antibiotics as a growth promoter on broiler performance, serum biochemistry, and immune responses, *Vet. World* 10 (2) (2017) 249–254.
- [31] M.I. Quereshi, Z. Quereshi, Effect of protein malnutrition on the weight and serum albumin of albino rats, *J. Ayub. Med. Coll. Abbotabad.* 13 (1) (2001) 8–10.
- [32] E.K.F. Batista, M.C.S. Batista, J.A.N. Sobrinho, H.I. Trindade, L.L.B. Silva, Muller, J.B.B.S. Influence of propolis on the leukocytes and proteins of mice and the closing time of excisions and infections by *Staphylococcus aureus*, *Ver Brasileira PI Med, Campinas* 17 (3) (2015) 413–419.
- [33] M.C. Ferraz, A.V.R. Matos, L.F. Moraes, R.O. Orsi, Propolis action on serum proteins and hematological aspects in marmosets (*Callithrix* sp) kept in captivity and subjected to stress, *Veterinária e Zootecnia* 18 (1) (2011) 70–80.
- [34] R.S. Kirsner, W.H. Eaglstein, The wound healing process, *Dermatol. Clin.* 11 (n. 4) (1993) 629–640.
- [35] N. Orsolic, I. Basic, Immunomodulation by eater soluble derivative of propolis: a factor of antitumor reactivity, *J. Ethnopharmacol.* 84 (2003) 265–273.
- [36] G. Fisher, S.O. Hubner, G.D. Vargas, T. Vidor, Immunomodulation induced by Propolis, *Arq. Inst. Biol.* 75 (2) (2008) 247–253.
- [37] D.C. Oliveira, A.A. Hastreiter, P. Borelli, R.A. Fock, A influência da desnutrição proteica sobre a produção de GM-CSF e M-CSF por macrofágos peritoneais, *Rev. Educac Cont Med Vet e Zootec* 13 (n. 1) (2015).
- [38] R.O. Orsi, E.R. Siqueira, Action of Propolis on Hematological Parameters and Serum Biochemistry and Its Effect on the Welfare of True Parrots (*Amazona Aestiva*) in Captivity. Dissertation (Master in Animal Science) – Universidade Estadual Paulista, Faculty of Veterinary Medicine and Animal Science, Campus Botucatu, Botucatu, São Paulo, 2011 pg. 20, 34 e 43.
- [39] S.P. Andrade, T.P. Fan, G.P. Lewis, Quantitative in-vivo studies on angiogenesis in a rat sponge model, *Br. J. Exp. Pathol.* 68 (6) (1987) 755–766.
- [40] D.S. Pereira, C.I.A. Freitas, M.O. Freitas, P.B. Maracajá, J.B.A. Silva, R.A. Silva, D.C. Silveira, History and main uses of bee propolis, *Agropecuária científica no semiárido* 11 (2) (2015) 01–21.
- [41] P. Carmeliet, R.K. Jain, Angiogenesis in cancer and other diseases, *Nature* 407 (2000) 249–257.
- [42] I. Dimova, G. Popivanov, V. Djonov, Angiogenesis in cancer – general pathways and their therapeutic implications, *Angiogenesis Cancer* 19 (1) (2014) 15–21.
- [43] R.J. Jeffrey, P.S. Michael, H.K. Charles, A.W. Derek, D.W. James, The codependence of angiogenesis and chronic inflammation, *Faseb J* 11 (1997) 457–465.
- [44] G.S. Firestein, Starving the synovium : angiogenesis and inflammation in rheumatoid arthritis see related article, *J. Clin. Invest.* 103 (1) (1999).
- [45] A.M. Brotas, J.M.T. Cunha, E.H.J.L. Lago, C.C.N. Machado, S.C.S.C. Carneiro, Tumor necrosis factor-alpha and the cytokine network in psoriasis, *Ann. Bras. Dermatol.* 87 (September-October (5)) (2012).